

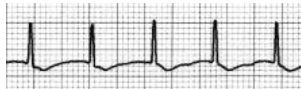
## CLINICAL PRACTICE

# Evaluation and Initial Treatment of Supraventricular Tachycardia

Mark S. Link, M.D.

*This Journal feature begins with a case vignette highlighting a common clinical problem. Evidence supporting various strategies is then presented, followed by a review of formal guidelines, when they exist. The article ends with the author's clinical recommendations.*

**A 24-year-old woman presents to the emergency department with the sole symptom of “a racing heart,” which began abruptly while she was eating dinner. She reports having had prior episodes of palpitations that resolved spontaneously. In the emergency room, her blood pressure is 84/60 mm Hg. An electrocardiogram (ECG) reveals a regular narrow-complex tachycardia at a rate of 190 beats per minute without clear atrial activity (P waves). How should this case be managed?**



## THE CLINICAL PROBLEM

From Tufts Medical Center, Tufts University School of Medicine, Boston. Address reprint requests to Dr. Link at Tufts Medical Center, 800 Washington St., Box #197, Boston, MA 02111, or at [mink@tuftsmedicalcenter.org](mailto:mink@tuftsmedicalcenter.org).

N Engl J Med 2012;367:1438-48.  
DOI: 10.1056/NEJMcp1111259

Copyright © 2012 Massachusetts Medical Society.

Patients with symptomatic tachycardias require immediate medical attention. Although it is commonly believed that a precise diagnosis of the tachycardia is necessary before therapy is initiated, immediate treatment can usually be tailored to the characteristics of the ventricular response. By focusing on the ventricular response, one can assign the seven clinically relevant supraventricular tachycardias to diagnostic and therapeutic groups on the basis of the rapidity of onset, the heart rate, and the regularity of the tachycardia (Fig. 1).<sup>1</sup> This review focuses on the initial diagnostic and therapeutic approach to supraventricular tachycardias and the ways of differentiating them from ventricular arrhythmias. Although atrial premature contractions are technically not a supraventricular tachycardia, this abnormality is included in the current discussion because it is often part of the differential diagnosis of supraventricular tachycardias.

### TYPES OF SUPRAVENTRICULAR TACHYCARDIAS

Sinus tachycardia, by far the most common supraventricular tachycardia, is not a pathologic arrhythmia (with the rare exception of inappropriate sinus tachycardia) but rather is an appropriate cardiac response to a physiological event (Fig. 1). Sinus tachycardia is gradual in onset and recession. The heart rate is regular and classically does not exceed 220 beats per minute minus the patient's age.<sup>2</sup> In sinus tachycardia, P waves precede the QRS complex.

Atrial fibrillation is the most common pathologic supraventricular tachycardia, affecting more than 3 million people in the United States<sup>3</sup> and many more worldwide.<sup>4</sup> Risk factors for atrial fibrillation include older age, male sex, hypertension, and underlying cardiac disease.<sup>5</sup> Atrial fibrillation is caused by multiple electrical wavelets appearing in the atria simultaneously, resembling the waves that would be produced if one dropped several pebbles in a bucket of water at the same time (Fig. 2). The arrhythmia is considered to be acute when it develops spontaneously in a person previously in normal sinus rhythm. In these cases, the heart rate may



An audio version of this article is available at [NEJM.org](http://NEJM.org)

## KEY CLINICAL POINTS

**DIFFERENTIAL DIAGNOSIS OF SUPRAVENTRICULAR TACHYCARDIAS**

- The initial differential diagnosis of supraventricular tachycardias should focus on the ventricular response characteristics of regularity, rate, and rapidity of onset, not on the atrial depolarization from the ECG.
- The regular supraventricular tachycardias include sinus tachycardia, atrial flutter, atrioventricular nodal reentrant tachycardia, atrioventricular reciprocating tachycardia, and atrial tachycardia.
- The irregular supraventricular tachycardias are atrial fibrillation, atrial flutter with variable atrioventricular block, and multifocal atrial tachycardia; multiple atrial premature contractions can cause a similar presentation.
- Sudden onset and termination are characteristic of acute atrial fibrillation and atrial flutter, atrioventricular nodal reentrant tachycardia, atrioventricular reciprocating tachycardia, and atrial tachycardia. Gradual onset and recession occur with sinus tachycardia, chronic atrial fibrillation and atrial flutter, multifocal atrial tachycardia, and atrial premature contractions.
- Adenosine blocks the atrioventricular node and is useful in distinguishing among supraventricular tachycardias but should not be given in the case of irregular wide-complex tachycardias, since it may render these rhythms unstable.
- After administration of adenosine, slowing of the heart rate is consistent with a diagnosis of sinus tachycardia, atrial tachycardia, atrial fibrillation, or atrial flutter, whereas termination of tachycardia points to atrioventricular nodal reentrant tachycardia, atrioventricular reciprocating tachycardia, and some atrial tachycardias.

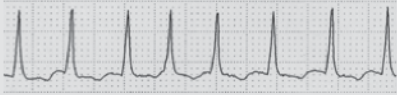
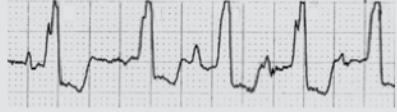
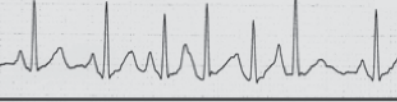


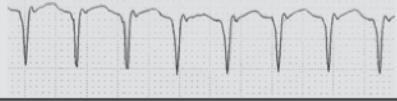

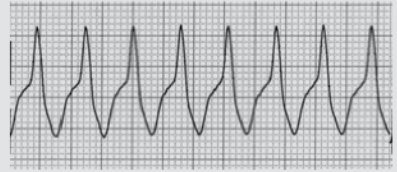
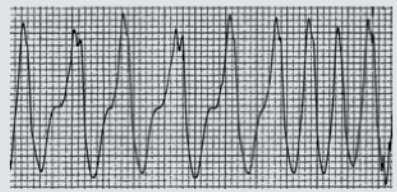

jump from 60 beats per minute to 160 beats per minute or more, and the patient is usually aware of this change. In contrast, in patients with chronic atrial fibrillation, the development of a rapid heart rate is more gradual and occurs in response to physical activity or other stressors — similar to the case with sinus tachycardia. With all cases of atrial fibrillation, the ventricular response is irregular, and the ventricular rate ranges from 60 to 220 beats per minute, depending largely on the patient's age, whether there is any underlying atrioventricular node disease, and whether the patient has received any drugs that affect the atrioventricular node.

Atrial flutter, the second most common pathologic supraventricular tachycardia, results from a reentrant circuit around the tricuspid valve in the right atrium (although atypical flutters do occur, primarily in persons who have undergone cardiac surgery or cardiac ablation) (Fig. 2). Atrial flutter is an organized regular rhythm that is generally characterized by an atrial rate of 280 to 300 beats per minute and that with 2:1 conduction in the atrioventricular node results in a ventricular rate of 140 to 150 beats per minute. At a heart rate of 150 beats per minute, the flutter waves are usually obscured by T waves, making the surface ECG

tracing for this tachycardia difficult to distinguish from that of other supraventricular tachycardias. However, a heart rate of 150 beats per minute is highly suggestive of this tachyarrhythmia. In patients who have atrioventricular node disease or who are receiving atrioventricular node–blocking medications, the rate in atrial flutter may be slower than 140 to 150 beats per minute. In these situations, the heart rate is irregular most of the time, although it is less chaotic than in atrial fibrillation.

The three next most common supraventricular tachycardias — atrioventricular nodal reentrant tachycardia, atrioventricular reciprocating (reentrant) tachycardia, and atrial tachycardia — are often considered to be a triumvirate because they share many characteristics, including rapid onset, heart rates of 150 to 250 beats per minute, and regularity of the ventricular response (Fig. 2). Atrioventricular nodal reentrant tachycardia and atrioventricular reciprocating tachycardia are caused by the presence of abnormal electrical circuits, whereas atrial tachycardia can be focal or caused by very small abnormal circuits. These supraventricular tachycardias occur in approximately 1 person per 500 in the United States.<sup>6</sup> Atrioventricular nodal reentrant tachycardia is

SVT	Underlying Causes	Regularity	Rate (beats/min)	Onset	Atrial Activity and P:QRS Relationship
Atrial fibrillation	Cardiac disease, pulmonary disease, pulmonary embolism, hyperthyroidism, postoperative	Irregular	100-220	Sudden or gradual (if in chronic atrial fibrillation)	Fibrillatory waves, no relationship to QRS
Multifocal atrial tachycardia	Pulmonary disease, theophylline therapy	Irregular	100-150	Gradual	Changing P morphologic features before QRS
Frequent atrial premature contractions	Caffeine, stimulants	Irregular	100-150	Gradual	P before QRS
Sinus tachycardia	Sepsis, hypovolemia, anemia, pulmonary embolism, pain, fear, fright, exertion, myocardial ischemia, hyperthyroidism, heart failure	Regular	220 minus the patient's age	Gradual	P before QRS
Atrial flutter	Cardiac disease	Regular (occasionally irregular if variable AV conduction)	150	Sudden	Flutter waves, usually 2:1
AV nodal reentrant tachycardia	None	Regular	150-250	Sudden	No apparent atrial activity or R' at termination of QRS
AV reciprocating tachycardia	Rarely, Ebstein's anomaly	Regular	150-250	Sudden	In narrow complex, P after QRS;  in wide complex, P rarely observed;  in irregular rhythm (atrial fibrillation), no apparent P wave
Atrial tachycardia	Cardiac disease, pulmonary disease	Regular	150-250	Sudden	P before QRS

Response to Adenosine	Electrocardiogram
Transient slowing of ventricular rate	
None	
None	
Transient slowing	
Transient slowing of ventricular rate	
Termination of tachycardia	
Termination of tachycardia	<p>Orthodromic AVRT</p>  <p>Antidromic AVRT</p>  <p>Atrial fibrillation with WPW</p> 
Termination of 60–80%	

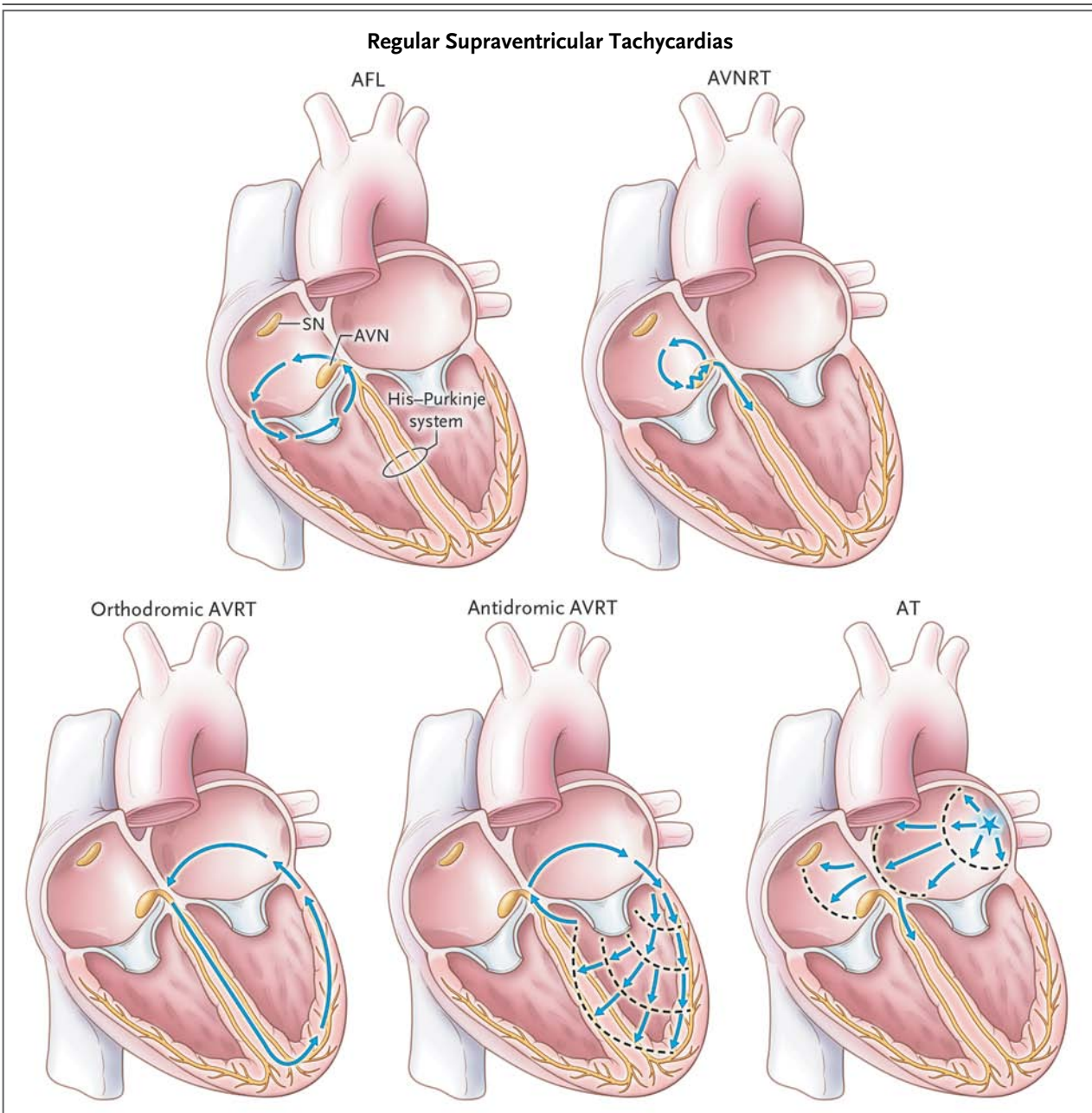
**Figure 1. Differential Diagnosis of the Supraventricular Tachycardias (SVTs), According to Regularity of Rhythm.**

AV denotes atrioventricular, AVRT atrioventricular reciprocating tachycardia, and WPW the Wolff–Parkinson–White syndrome.

most common among persons older than 20 years of age, whereas atrioventricular reciprocating tachycardia occurs more frequently in the pediatric population. Atrial tachycardia is the least common of the three.

Atrioventricular nodal reentrant tachycardia is caused by a reentrant loop that involves the atrioventricular node and the atrial tissue.<sup>7</sup> In persons with this type of tachycardia, the atrioventricular node has two conduits, one of which conducts rapidly and the other slowly. The slower pathway, which lies parallel to the tricuspid valve, allows for a reentrant loop as the electrical impulse meanders through the slow pathway, exiting the atrioventricular node in a retrograde manner (i.e., backward from the atrioventricular node to the atrium) and in an anterograde manner (i.e., forward, or from the atrioventricular node to the ventricle) at the same time. Because of the simultaneous depolarization of the atrium and ventricle, P waves are rarely seen on the surface ECG, although atrial depolarization can occasionally be seen as part of the terminal QRS complex in lead V<sub>1</sub>.

Atrioventricular reciprocating tachycardia is caused by cardiac musculature that bypasses the normal insulation afforded by the tricuspid and mitral valves between the atria and the ventricles. These bypass tracts may conduct in an anterograde direction only, in a retrograde direction only, or in both directions. A delta wave, an initial slurring of the QRS complex, is present on the surface ECG in most cases of anterograde bypass tracts and indicates partial depolarization of the ventricular tissue resulting from rapid conduction of the electrical impulse from the atrium to the ventricle over the bypass tract. Delta waves are absent in cases in which there is no anterograde conduction and in some persons with left atrial free-wall bypass tracts (since the brisk atrioventricular node conduction can depolarize the ventricle through the His–Purkinje system before the atrial impulse arrives at the bypass tract). Patients who have both tachycardia and a delta wave have the Wolff–Parkinson–White syndrome. Patients



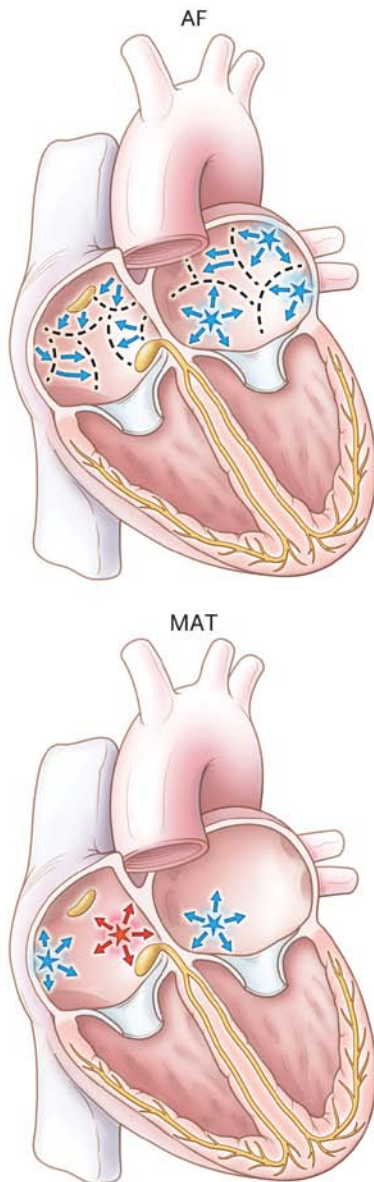
**Figure 2. Mechanisms of Supraventricular Tachycardias, According to Regularity of Rhythm.**

The regular supraventricular tachycardias include sinus tachycardia (not shown), atrial flutter (AFL), atrioventricular nodal reentrant tachycardia (AVNRT), atrioventricular reciprocating tachycardia (AVRT), and atrial tachycardia (AT). Orthodromic AVRT is much more common than antidromic AVRT. The irregular supraventricular tachycardias include atrial fibrillation (AF), AFL when it occurs in a patient with variable AV block (not shown), multifocal atrial tachycardia (MAT), and sinus rhythm with multiple atrial premature beats (not shown). AVN denotes atrioventricular node, and SN sinus node.

with a surface delta wave but no tachycardia have ECG findings similar to those with the Wolff-Parkinson-White syndrome but do not have the syndrome. Nonetheless, these persons are still at risk for supraventricular tachycardias. Three ar-

rhythmias are seen with bypass tracts: a narrow regular QRS complex (orthodromic; conduction down the atrioventricular node and retrograde conduction through the bypass tract), a wide regular QRS complex (antidromic; conduction down

### Irregular Supraventricular Tachycardias



the bypass tract and retrograde conduction through the atrioventricular node), and a wide irregular QRS complex (atrial fibrillation) (Fig. 1 and 2). In atrioventricular reciprocating tachycardia, atrial activity (P waves) may be seen after the QRS complex, although this atrial depolarization is often obscured by the T wave. When atrial fibrillation occurs, the ventricular rate can be quite rapid and can lead to fatal ventricular arrhythmias.

Atrial tachycardia is a focal tachycardia that may be a result of a micro-reentrant circuit or an

automatic focus. There are two unique characteristics of atrial tachycardias: they may occur in repetitive short bursts, and they are frequently characterized by a warm-up phenomenon in which the atrial rate increases slightly over the first 5 to 10 seconds before stabilizing. Surface ECGs show a P wave preceding each QRS complex, although at rapid heart rates, the P wave may be obscured by the T wave.

The remaining supraventricular tachycardias are much less common. Multifocal atrial tachycardia occurs because of multiple atrial premature beats in an atrium poisoned by hypoxia, increased atrial pressure, and, perhaps most important, theophylline. This type of tachycardia is uncommon today because of the reduced use of theophylline in the treatment of pulmonary disease. Multifocal atrial tachycardia is gradual in onset because the underlying rhythm is generally sinus tachycardia, and the heart rates with multifocal atrial tachycardia are only slightly faster than these baseline rates. The rhythm is irregular, and on ECG, P waves with abnormal morphologic characteristics (with three abnormal P waves necessary for the diagnosis) precede each QRS complex.

Frequent atrial premature contractions, although not technically a supraventricular tachycardia, warrant mention because they are commonly confused with supraventricular tachycardias. Like atrial tachycardia, frequent atrial premature contractions originate from a single focus; therefore, the morphologic characteristics of the P wave are similar to those seen with atrial tachycardia. This rhythm can be sudden or gradual in onset, depending on the underlying sinus rate. The rhythm is irregular, with heart rates between 100 and 150 beats per minute.

Other supraventricular tachycardias are so uncommon that most practicing physicians are unlikely ever to observe them. Junctional tachycardia is extremely rare in adults but can occur in infants. Two other types of unusual tachycardias are thought to originate from abnormal atrioventricular nodal tissue that is separated from the atrioventricular node. Paroxysmal junctional retrograde tachycardia occurs with a bypass tract near the atrioventricular node that conducts in only a retrograde direction. The tachycardia usually is incessant and often causes a dilated cardiomyopathy. Mahaim fiber tachycardias are caused by tissue that originates in the lateral right atrium and connects to the distal right bundle branch. A wide-complex reentrant tachycardia occurs

with conduction down the abnormal tissue and back up to the atrium through the atrioventricular node.

---

## STRATEGIES AND EVIDENCE

---

### DIFFERENTIAL DIAGNOSIS OF SUPRAVENTRICULAR TACHYCARDIAS

The initial differential diagnosis of supraventricular tachycardias should focus on the ventricular response, not on atrial depolarization as observed on the ECG. The first step is to determine whether the QRS complex is narrow or wide. Then regularity should be assessed (Fig. 1). Regularity is defined as variation of less than 10% in beat-to-beat timing, but most regular tachycardias actually vary by less than 5%.<sup>8</sup> After regularity is assessed, the rapidity of onset and offset should be determined, preferably by means of cardiac monitoring, although it can be assessed on the basis of the history. The heart rate should also be considered in the differential diagnosis of supraventricular tachycardias.

### NARROW-COMPLEX SUPRAVENTRICULAR TACHYCARDIAS

Only after the differential diagnosis has been narrowed on the basis of the features mentioned above should atrial activity be assessed. P waves immediately precede the QRS complex in sinus tachycardia, atrial tachycardia, multifocal atrial tachycardia, and multiple atrial premature contractions. P waves follow the QRS complex in atrioventricular nodal reentrant tachycardia and atrioventricular reciprocating tachycardia. In tachycardias with very rapid heart rates (e.g., atrial tachycardia, atrioventricular nodal reentrant tachycardia, and atrioventricular reciprocating tachycardia), P waves may not be apparent owing to overlap of the T wave. Atrial flutter with 2:1 conduction block can easily be mistaken for sinus tachycardia or atrial tachycardia because a flutter wave is often buried in the T wave; however, a rate of 150 beats per minute should lead one to suspect atrial flutter. Finally, the response to administration of adenosine can assist in the diagnosis of a specific supraventricular tachycardia (Fig. 3) (see below for additional information regarding adenosine).

### WIDE-COMPLEX SUPRAVENTRICULAR TACHYCARDIAS

In contrast to narrow-complex tachycardias, which can be generated only by impulses that

depolarize the ventricle through the His–Purkinje system (and thus are, by definition, supraventricular tachycardias), wide-complex tachycardias can be ventricular or supraventricular in origin (or artifactual). Wide-complex tachycardias are caused by ventricular arrhythmia (ventricular tachycardia, ventricular fibrillation, and torsades de pointes or polymorphic ventricular tachycardia) or supraventricular tachycardias with aberrant conduction resulting from one of the following conditions: disease in the His–Purkinje system, such as left or right bundle-branch block; a bypass tract (i.e., the Wolff–Parkinson–White syndrome), with depolarization of the ventricle from the bypass tract; or a ventricular paced rhythm from a pacemaker. Wide-complex tachycardias can be regular or irregular. Regular wide-complex tachycardias are either ventricular tachycardia or regular supraventricular tachycardias (Fig. 3), whereas irregular wide-complex tachycardias are either the ventricular arrhythmias of polymorphic ventricular tachycardia, torsades de pointes, or ventricular fibrillation or one of the irregular supraventricular tachycardias (Fig. 4).

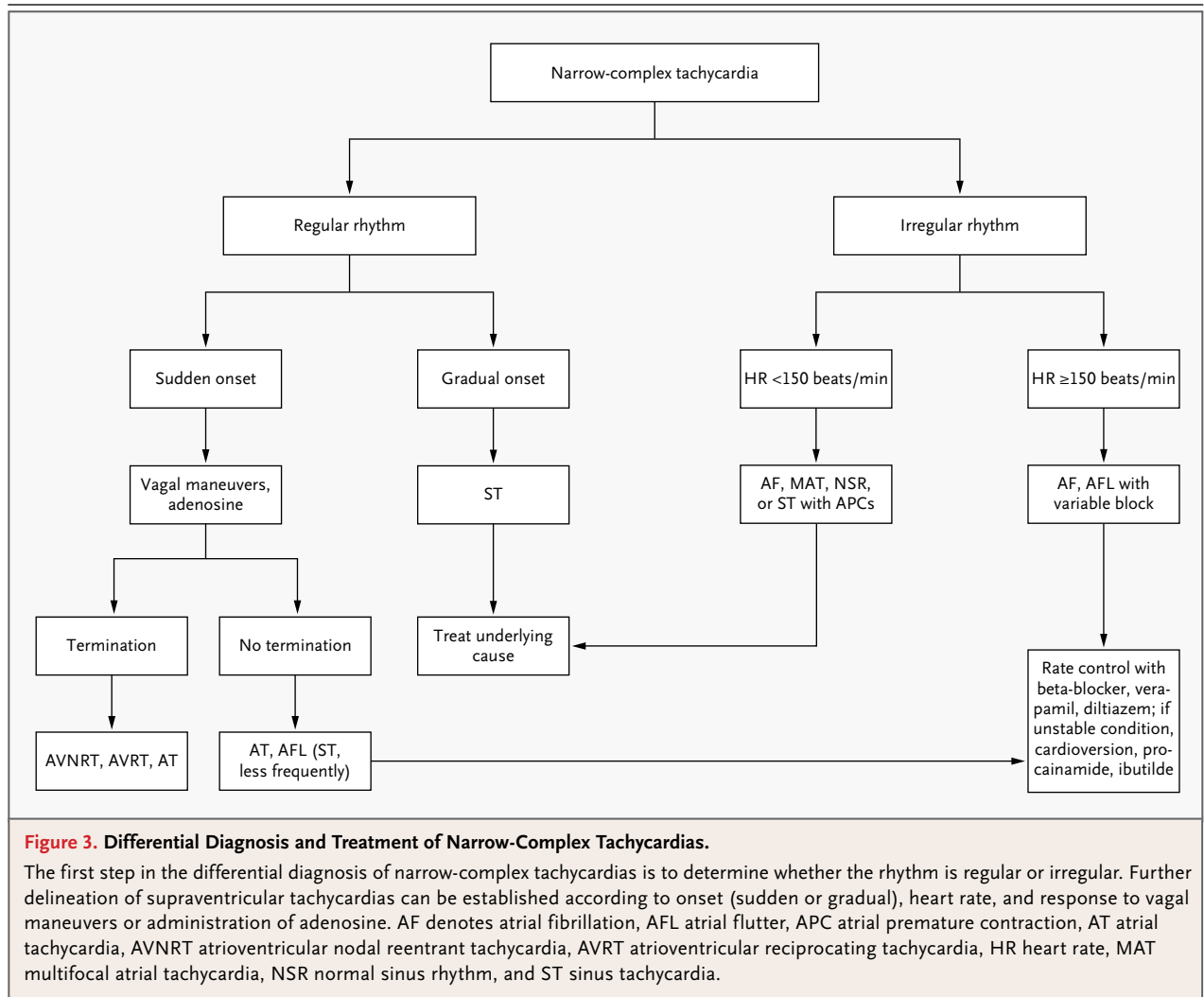
---

## MANAGEMENT

---

### NARROW-COMPLEX TACHYCARDIAS

Vagal maneuvers and administration of adenosine are useful in the diagnosis and treatment of narrow-complex supraventricular tachycardias.<sup>9</sup> Vagal maneuvers — including a Valsalva maneuver, carotid sinus massage, bearing down, and immersion of the face in ice water — increase vagal tone and block the atrioventricular node. The resulting slowing of the heart rate often confirms the diagnosis of sinus tachycardia, atrial fibrillation, or atrial flutter and can frequently terminate atrioventricular nodal reentrant tachycardia and atrioventricular reciprocating tachycardia. Adenosine, a very short-acting endogenous nucleotide that blocks atrioventricular nodal conduction, terminates nearly all atrioventricular nodal reentrant tachycardias and atrioventricular reciprocating tachycardias as well as up to 80% of atrial tachycardias.<sup>10</sup> Adenosine should be administered quickly at a dose of 6 mg, followed by a bolus of 20 ml of fluid. Since this drug may also excite atrial and ventricular tissue, causing atrial fibrillation in up to 12% of patients and nonsustained ventricular tachycardia in rare cases,<sup>11</sup> it should be administered only when a cardiac monitor is being used and a defibrillator is on



hand. A lower dose (3 mg) is recommended in persons who have a cardiac transplant or in whom the drug is administered through a central catheter. Adenosine should not be used in patients with bronchospastic lung disease. Common side effects include chest tightness, flushing, and a sense of dread.

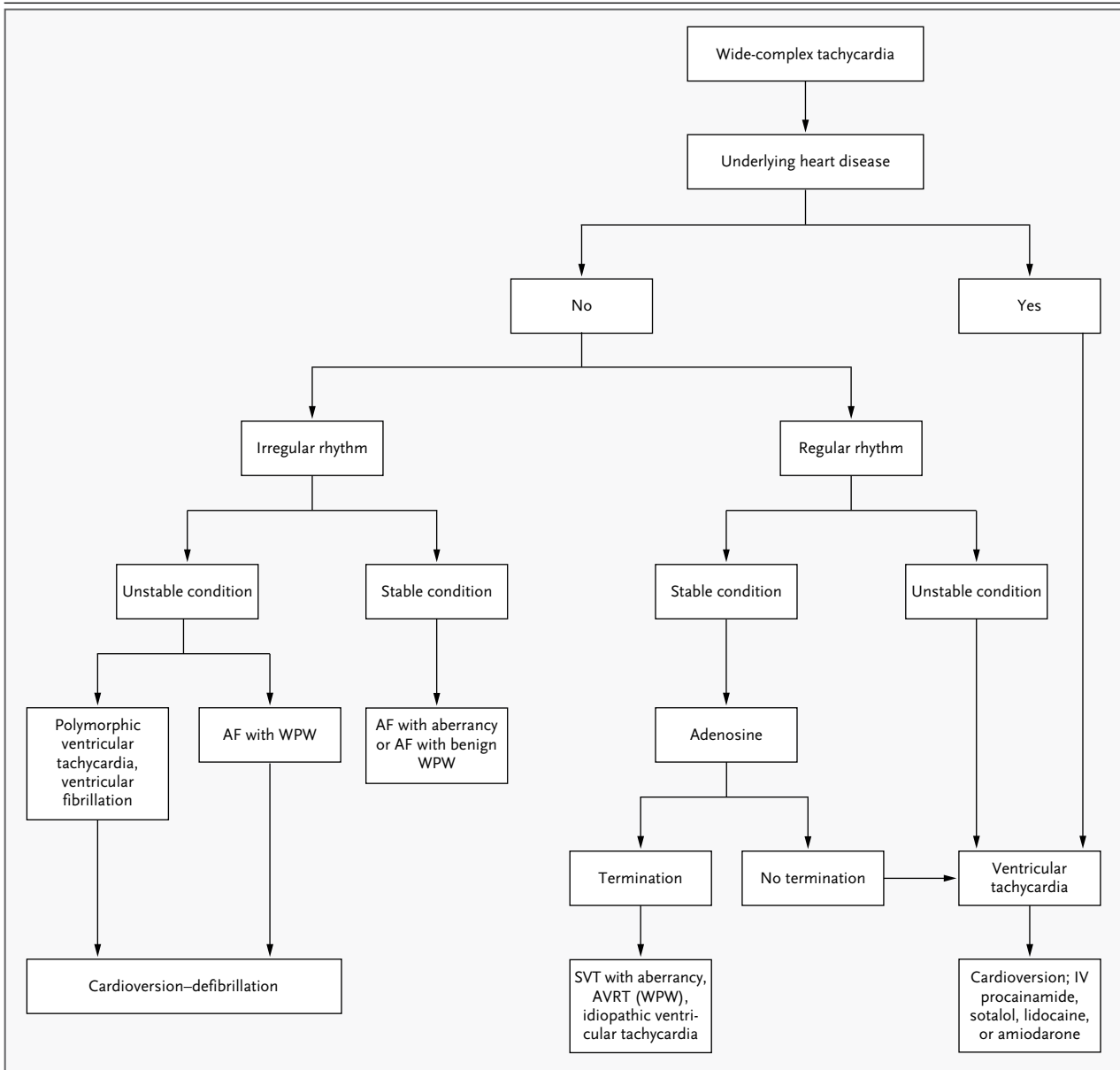
Although intravenous verapamil and diltiazem, which also block the atrioventricular node, are of potential diagnostic and therapeutic use in narrow-complex tachycardia, they may cause hypotension and thus are not a first choice in the emergency setting.<sup>12</sup> Electrical cardioversion is reserved for patients in unstable condition who are not having a response to adenosine. Antiarrhythmic agents are rarely necessary in the early management of supraventricular tachycardias, with the exception of the management of arrhyth-

mias that have caused hemodynamic instability and that have not responded to electrical cardioversion. In these cases, procainamide and ibutilide can be used.<sup>10</sup>

#### WIDE-COMPLEX TACHYCARDIAS

Adenosine is also useful in the differential diagnosis and treatment of wide-complex tachycardias,<sup>13</sup> but it should be given only when these tachycardias are regular, since irregular wide-complex tachycardias may be rendered unstable after the administration of adenosine. Potential risks include increasing conduction through a bypass tract if the underlying arrhythmia is atrial fibrillation or (more worrisome) terminating the supraventricular tachycardia but inducing atrial fibrillation with resultant rapid conduction down a bypass tract, leading to ventricular fibrillation.<sup>11</sup> Verapamil and diltiazem





**Figure 4. Differential Diagnosis and Treatment of Wide-Complex Tachycardias.**

In the differential diagnosis of wide-complex tachycardias, the initial step is to determine whether there is underlying heart disease. If the patient has known or suspected cardiac disease, the tachycardia is probably a ventricular tachycardia, and treatment for that condition should be initiated. If heart disease is not thought to be present, the strategy is to separate the ventricular response into regular and irregular rhythms. If a patient with a regular wide-complex tachycardia is in stable condition, administration of adenosine is reasonable, since this will terminate many of the supraventricular tachycardias. If the patient's condition is unstable, or if the tachycardia does not terminate with adenosine, treatment for presumptive ventricular tachycardia (i.e., cardioversion) should be given. Irregular wide-complex tachycardias are always worrisome, since they are frequently unstable. Patients with unstable irregular wide-complex tachycardias should undergo cardioversion; if the tachycardias are stable, monitoring and cardiac consultation are appropriate. AF denotes atrial fibrillation, AVRT atrioventricular reciprocating tachycardia, IV intravenous, SVT supraventricular tachycardia, and WPW the Wolff-Parkinson-White syndrome.

should not be administered in patients with wide-complex tachycardias, since profound hypotension and death may occur.<sup>12</sup> Electrical cardioversion is necessary in the treatment of unstable wide-com-

plex tachycardias, as it is in the treatment of unstable narrow-complex tachycardias. Procainamide and ibutilide, as well as lidocaine, amiodarone, and sotalol, are useful in the treatment of wide-complex

tachycardias.<sup>10</sup> Stable wide-complex irregular tachycardias are usually atrial fibrillation with aberrancy or the Wolff–Parkinson–White syndrome; in the case of these arrhythmias, consultation with an expert is generally required.

#### AREAS OF UNCERTAINTY

Arrhythmias causing hemodynamic instability (hypotension, heart failure, or coronary ischemia) require urgent electrical cardioversion. However, it is often unclear, especially in the case of atrial fibrillation, whether the supraventricular tachycardia is the cause or the result of the hemodynamic instability.<sup>10</sup> In many patients, rapid atrial fibrillation is a consequence rather than a cause of heart failure or cardiac ischemia. Atrial fibrillation is rarely the cause of instability when heart rates are less than 150 beats per minute.<sup>10</sup>

#### GUIDELINES

Guidelines for the early treatment of supraventricular tachycardias are included in the 2010 American Heart Association Advanced Cardiovascular Life Support guidelines.<sup>10,14</sup> The recommendations provided here are generally consistent with these guidelines, including administration of adenosine as the initial treatment of choice for regular supraventricular tachycardias and as an important aid in the differential diagnosis of regular wide-complex tachycardias.

#### CONCLUSIONS AND RECOMMENDATIONS

In a patient presenting with symptomatic tachycardia, such as the woman described in the vignette, prompt evaluation and treatment are

needed. Although the blood pressure of the woman in the vignette is 84/60 mm Hg, she is alert and has no signs of shock; thus, her condition is not considered to be unstable. The initial assessment should distinguish between narrow- and wide-complex tachycardia, determine whether the rhythm is regular or irregular, and consider the rapidity of onset. This patient has a regular narrow-complex tachycardia with a sudden onset, as assessed on the basis of the history. Possibilities include atrial flutter, atrioventricular nodal reentrant tachycardia, atrioventricular reciprocating tachycardia, and atrial tachycardia. The narrow QRS complex rules out ventricular tachycardia; the regular response rules out atrial fibrillation and multifocal atrial tachycardia. The heart rate of 190 beats per minute is inconsistent with atrial flutter. Furthermore, the suddenness of the onset of symptoms and the absence of clear P waves suggest atrioventricular nodal reentrant tachycardia, atrioventricular reciprocating tachycardia, or atrial tachycardia. Adenosine should be administered with the patient on a cardiac monitor, with a cardiac defibrillator at hand. Adenosine would be expected to terminate the supraventricular tachycardia. An ECG should be evaluated when sinus rhythm is restored; the presence of a delta wave would be consistent with a diagnosis of atrioventricular reciprocating tachycardia caused by the Wolff–Parkinson–White syndrome.

Dr. Link reports receiving consulting fees from Lantheus Medical Imaging and holding patents for a chest-wall protector for sports and a testing model for commotio cordis. No other potential conflict of interest relevant to this article was reported.

Disclosure forms provided by the author are available with the full text of this article at NEJM.org.

I thank Dr. Bonnie L. Bermas for her careful review of an earlier version of the manuscript, and Steven Moskowitz of Advanced Medical Graphics for his assistance with earlier versions of the figures.

#### REFERENCES

- Link MS. Introduction to the arrhythmias: a primer. *EP Lab Digest* 2007;5:38-9.
- Fox SM III, Naughton JP, Haskell WL. Physical activity and the prevention of coronary heart disease. *Ann Clin Res* 1971; 3:404-32.
- Naccarelli GV, Varker H, Lin J, Schulman KL. Increasing prevalence of atrial fibrillation and flutter in the United States. *Am J Cardiol* 2009;104:1534-9.
- Heeringa J, van der Kuip DA, Hofman A, et al. Prevalence, incidence and lifetime risk of atrial fibrillation: the Rotterdam study. *Eur Heart J* 2006;27:949-53.
- Schnabel RB, Sullivan LM, Levy D, et al. Development of a risk score for atrial fibrillation (Framingham Heart Study): a community-based cohort study. *Lancet* 2009;373:739-45.
- Orejarena LA, Vidaillet H Jr, DeStefano F, et al. Paroxysmal supraventricular tachycardia in the general population. *J Am Coll Cardiol* 1998;31:150-7.
- Katritsis DG, Camm AJ. Atrioventricular nodal reentrant tachycardia. *Circulation* 2010;122:831-40.
- Buxton AE, Calkins H, Callans DJ, et al. ACC/AHA/HRS 2006 key data elements and definitions for electrophysiological studies and procedures: a report of the American College of Cardiology/American Heart Association Task Force on Clinical Data Standards (ACC/AHA/HRS Writing Committee to Develop Data Standards on Electrophysiology). *Circulation* 2006;114:2534-70.
- diMarco JP, Sellers TD, Lerman BB, Greenberg ML, Berne RM, Belardinelli L. Diagnostic and therapeutic use of adenosine in patients with supraventricular tachyarrhythmias. *J Am Coll Cardiol* 1985; 6:417-25.
- Neumar RW, Otto CW, Link MS, et al. Part 8: adult advanced cardiovascular life support: 2010 American Heart Association Guidelines for Cardiopulmonary Resuscitation and Emergency Cardiovascular Care. *Circulation* 2010;122:Suppl 3:S729-S767. [Erratum, *Circulation* 2011;123(6):e236.]

11. Strickberger SA, Man KC, Daoud EG, et al. Adenosine-induced atrial arrhythmia: a prospective analysis. *Ann Intern Med* 1997;127:417-22. [Erratum, *Ann Intern Med* 1998;128:511.]
12. Delaney B, Loy J, Kelly AM. The relative efficacy of adenosine versus verapamil for the treatment of stable paroxysmal supraventricular tachycardia in adults: a meta-analysis. *Eur J Emerg Med* 2011;18:148-52.
13. Marill KA, Wolfram S, Desouza IS, et al. Adenosine for wide-complex tachycardia: efficacy and safety. *Crit Care Med* 2009;37:2512-8.
14. Link MS, Atkins DL, Passman RS, et al. Part 6: electrical therapies: automated external defibrillators, defibrillation, cardioversion, and pacing: 2010 American Heart Association Guidelines for Cardiopulmonary Resuscitation and Emergency Cardiovascular Care. *Circulation* 2010;122:Suppl 3:S706-S719. [Erratum, *Circulation* 2011;123(6):e235.]

Copyright © 2012 Massachusetts Medical Society.