

STATE-OF-THE-ART REVIEW

Acute Management of Ventricular Arrhythmia in Patients With Suspected Inherited Heart Rhythm Disorders



Zachary Laksman, MD, MSc, Scott Barichello, MD, Thomas M. Roston, MD, Marc W. Deyell, MD, MSc, Andrew D. Krahn, MD

JACC: CLINICAL ELECTROPHYSIOLOGY CME/MOC/ECME

This article has been selected as this month's *JACC: Clinical Electrophysiology* CME/MOC/ECME activity, available online at <http://www.acc.org/jacc-journals-cme> by selecting the *JACC Journals CME/MOC/ECME* tab.

Accreditation and Designation Statement

The American College of Cardiology Foundation (ACCF) is accredited by the Accreditation Council for Continuing Medical Education (ACCME) and the European Board for Accreditation in Cardiology (EBAC) to provide continuing medical education for physicians.

The ACCF designates this Journal-based CME/MOC/ECME activity for a maximum of 1 AMAPRA Category 1 Credit or 1 EBAC Credit. Physicians should only claim credit commensurate with the extent of their participation in the activity.

Method of Participation and Receipt of CME/MOC/ECME Certificate

To obtain credit for *JACC: Clinical Electrophysiology* CME/MOC/ECME, you must:

1. Be an ACC member or JACEP subscriber.
2. Carefully read the CME/MOC/ECME-designated article available online and in this issue of the journal.
3. Answer the post-test questions. A passing score of at least 70% must be achieved to obtain credit.
4. Complete a brief evaluation.
5. Claim your CME/MOC/ECME credit and receive your certificate electronically by following the instructions given at the conclusion of the activity.

Acute Management of Ventricular Arrhythmia in Patients With Suspected Inherited Heart Rhythm Disorders will be accredited by the **European Board for Accreditation in Cardiology (EBAC)** for 1 hour of External CME

credits. Each participant should claim only those hours of credit that have actually been spent in the educational activity. The Accreditation Council for Continuing Medical Education (ACCME) and the European Board for Accreditation in Cardiology (EBAC) have recognized each other's accreditation systems as substantially equivalent. Apply for credit through the post-course evaluation.

CME/MOC/ECME Objective for This Article: Upon completion of this activity, the learner should be able to: 1) review clinical presentations of patients with inherited arrhythmia syndromes presenting with ventricular arrhythmias; 2) compare and contrast the acute management of patients with suspected inherited arrhythmia syndromes to patients with ischemic or structural cardiomyopathies; 3) highlight early decision stems which facilitate appropriate management; and 4) identify important provoking and alleviating factors for ventricular arrhythmias in specific inherited arrhythmia syndromes.

CME/MOC/ECME Editor Disclosure: CME/MOC/ECME Editor Smit Vasaiwala, MD, has reported that he has nothing to declare.

Author Disclosures: The authors have reported that they have no relationships relevant to the contents of this paper to disclose.

Medium of Participation: Print (article only); online (article and quiz).

CME/MOC/ECME Term of Approval

Issue Date: March 2019

Expiration Date: February 29, 2020

From the Heart Rhythm Services, Division of Cardiology, Department of Medicine, University of British Columbia, Vancouver, British Columbia, Canada. The authors have reported that they have no relationships relevant to the contents of this paper to disclose.

All authors attest they are in compliance with human studies committees and animal welfare regulations of the authors' institutions and Food and Drug Administration guidelines, including patient consent where appropriate. For more information, visit the *JACC: Clinical Electrophysiology* [author instructions page](#).

Manuscript received December 20, 2018; revised manuscript received February 2, 2019, accepted February 3, 2019.

Acute Management of Ventricular Arrhythmia in Patients With Suspected Inherited Heart Rhythm Disorders

Zachary Laksman, MD, MSc, Scott Barichello, MD, Thomas M. Roston, MD, Marc W. Deyell, MD, MSc, Andrew D. Krahn, MD

ABSTRACT

After the most common causes of sudden cardiac death including ischemic and structural heart disease have been ruled out, clinicians on the front lines of emergent medical care can be faced with unexplained and recurrent life-threatening arrhythmia episodes in children and adults. In these cases, an inherited arrhythmia syndrome should be suspected, and a departure from conventional advanced cardiac life support algorithms may be required. This review focuses on the electrocardiographic clues of an inherited arrhythmia syndrome that can be uncovered through a careful analysis of the baseline electrocardiogram (ECG) and classification of the presenting ventricular arrhythmia and its mode of onset. After presenting an informed working diagnosis and an explanation of the implied electrophysiologic mechanisms, discussion provides a protocol approach to acute and subacute management decisions. Careful attention to a patient's response to treatment and its ECG surrogates have the potential to facilitate tailored therapy based on the underlying arrhythmogenic substrate and pathophysiology. (J Am Coll Cardiol EP 2019;5:267-83) © 2019 by the American College of Cardiology Foundation.

Cardiac arrest leading to sudden cardiac death (SCD) remains a common cause of death, accounting for 15% to 20% of the mortality in the industrialized countries, with coronary artery and structural heart disease implicated in most cases (1). After these causes have been excluded, an inherited arrhythmia syndrome will be identified in more than one-half of the remaining patients (2). In selected populations, however, such as children and competitive athletes, the incidence of inherited arrhythmia episodes and arrhythmogenic cardiomyopathies responsible for SCD is dramatically increased (3). Subsequent clinical follow-up, genetic testing, and cascade screening have the potential to determine the cause of death and tailor therapy in an increasing number of patients and families; however, a definitive diagnosis is often elusive at initial presentation (4,5). The acute management of both inherited arrhythmia syndromes and arrhythmogenic cardiomyopathies when the patient presents with unstable ventricular arrhythmia requires therapies targeted at underlying pathophysiology that are distinct from routine resuscitation algorithms, and thus, appropriate early recognition and a high degree of suspicion are of utmost importance.

This review focuses on electrocardiographic (ECG) clues, with an emphasis on identifying and differentiating arrhythmic modes of initiation, which have

the potential to guide initial management in the absence of a definite underlying diagnosis (**Central Illustration**). Management can be refined as the clinician evaluates the patient's response to therapy, including a careful assessment of dynamic ECG metrics (**Table 1, Online Table S1**).

CLINICAL SCOPE AND BURDEN

The overall incidence of life-threatening symptoms, such as an aborted cardiac arrest or electrical storm (≥ 3 ventricular fibrillation [VF] episodes in 24 h), among patients with inherited arrhythmia syndromes is largely unknown. This is largely because subclinical cases of inherited arrhythmia episodes are being increasingly identified. For example, in a large prospective and modern long-QT syndrome (LQTS) cohort, only 4% of patients presented with SCD, aborted cardiac arrest, or hemodynamically non-tolerated polymorphic ventricular tachycardia (PMVT) (6). Patients in this cohort had relatively shorter QT intervals than reported in previous studies, suggesting a contemporary trend toward improved identification of subclinical cases. In Brugada syndrome (BrS), the risk of a life-threatening event at presentation is probably higher. The SABRUS (Survey on Arrhythmic Events in Brugada Syndrome) study of 678 BrS patients showed that more

HIGHLIGHTS

- Ventricular arrhythmias in a patient without structural or ischemic heart disease should raise suspicion for the presence of an underlying inherited heart rhythm disorder.
- Employment of ACLS protocols in patients with inherited arrhythmia syndromes may actually promote arrhythmia; therefore, it is essential that clinicians have an expeditious and reliable approach for identifying the specific etiology and providing tailored therapy.
- This review focuses on the analysis of the patient's baseline ECG and mode of initiation of the presenting arrhythmia to aid in the bedside management of a patient with a suspected underlying inherited arrhythmia syndrome based on currently available evidence.
- Where clinical experience and best practice guidelines are lacking, large ongoing registries and well designed clinical trials are required to bridge the knowledge gap that remains between our understanding of pathophysiologic mechanisms and clinical outcomes.

than one-half experienced an aborted cardiac arrest as their first arrhythmic event and that BrS was more common in younger patients (7). In the Pediatric and Congenital Electrophysiology Society (PACES) catecholaminergic polymorphic ventricular tachycardia (CPVT) registry, an international study of children and their first-degree relatives with CPVT, 38% of 226 patients experienced an occurrence of aborted cardiac arrest at initial presentation (8). The risk of recurrent life-threatening episodes is highest in CPVT, wherein one-fourth of patients have treatment failure during follow-up, and 1 in 5 recipients of an implantable cardioverter-defibrillator (ICD) will have an electrical storm (9). In such scenarios, the clinician must also be prepared to implement adjunctive therapies in patients with established, treated inherited arrhythmia syndromes. The treatment of ventricular arrhythmia episodes may be complex and requires care from an expert multidisciplinary team. Specialists who may be involved include cardiac electrophysiologists, heart failure specialists, cardiac anesthesiologists, and cardiac surgeons. Recently, a model for

multidisciplinary team management of patients with VT has been described (10). There is also evidence that the use of a dedicated VT unit may improve long-term outcomes (11).

WHEN AND WHY CLINICIANS SHOULD SUSPECT AN INHERITED ARRHYTHMIA SYNDROME

Despite early and aggressive resuscitation in patients who present with shockable rhythms, as many as 1 in 5 will go on to experience recurrent life-threatening arrhythmic events in the form of recurrent PMVT or VF, resulting in an increase in mortality (12). Up to 10% of all cardiac arrest patients will not have coronary artery disease or structural heart disease, and a preponderance of younger patients will not have comorbid conditions. In many cases, these patients will not respond to conventional resuscitative algorithms such as lidocaine or amiodarone therapy, which have the potential to exacerbate the pro-arrhythmic state and lead to clinical deterioration (3,13). When these patients present with recurrent cardiac arrest, recurrent sustained and non-sustained ventricular arrhythmias, or recurrent ICD shocks, the resuscitative efforts must include a thoughtful search for clues that can link the presentation to a suspected diagnosis in order to inform management (Figure 1, Online Table S1) (14). A clinical history should always be obtained from the patient or collateral persons if the situation allows, as this may provide further evidence to support the presence of an inherited arrhythmia (family history of SCD) as well as to suggest specific syndromes. For example, a personal history of exertion- or stress-induced syncope may raise the clinician's suspicion of CPVT (notably, a normal baseline ECG); whereas a history of night time agonal breathing may suggest BrS.

EVALUATION OF THE BASELINE ECG

The baseline ECG should be reviewed for: 1) assessment of heart rate; 2) changes in depolarization (looking for conduction system disease and fractionation); and 3) changes in repolarization (including late repolarization in terms of QT and QT-corrected interval and early repolarization in terms of J waves, ST-segments, and notching) (Online Table S2).

A number of disease entities, however, may present with normal resting ECGs, including CPVT, short-coupled VF (SC-VF), latent inherited

ABBREVIATIONS AND ACRONYMS

ICD = implantable cardioverter-defibrillator

PMVT = polymorphic ventricular tachycardia

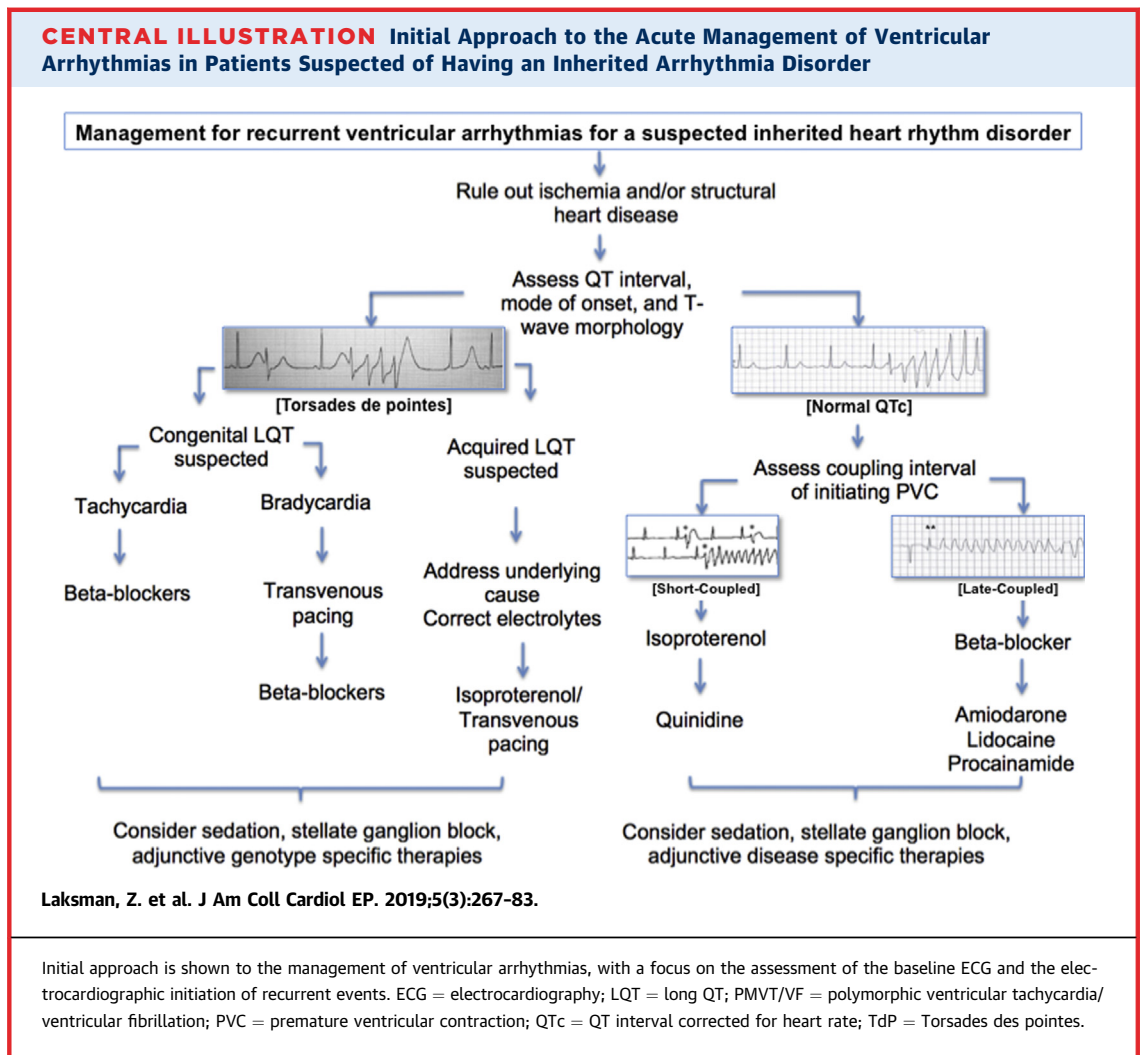
PVC = premature ventricular contraction

SCD = sudden cardiac death

TdP = Torsades des pointes

VF = ventricular fibrillation

VT = ventricular tachycardia



cardiomyopathies, and early forms of infiltrative cardiomyopathies. In patients with genetically confirmed LQTS, for example, between 5% and 17% of patients will have a normal QT interval corrected for heart rate (QTc), depending on genotype, although

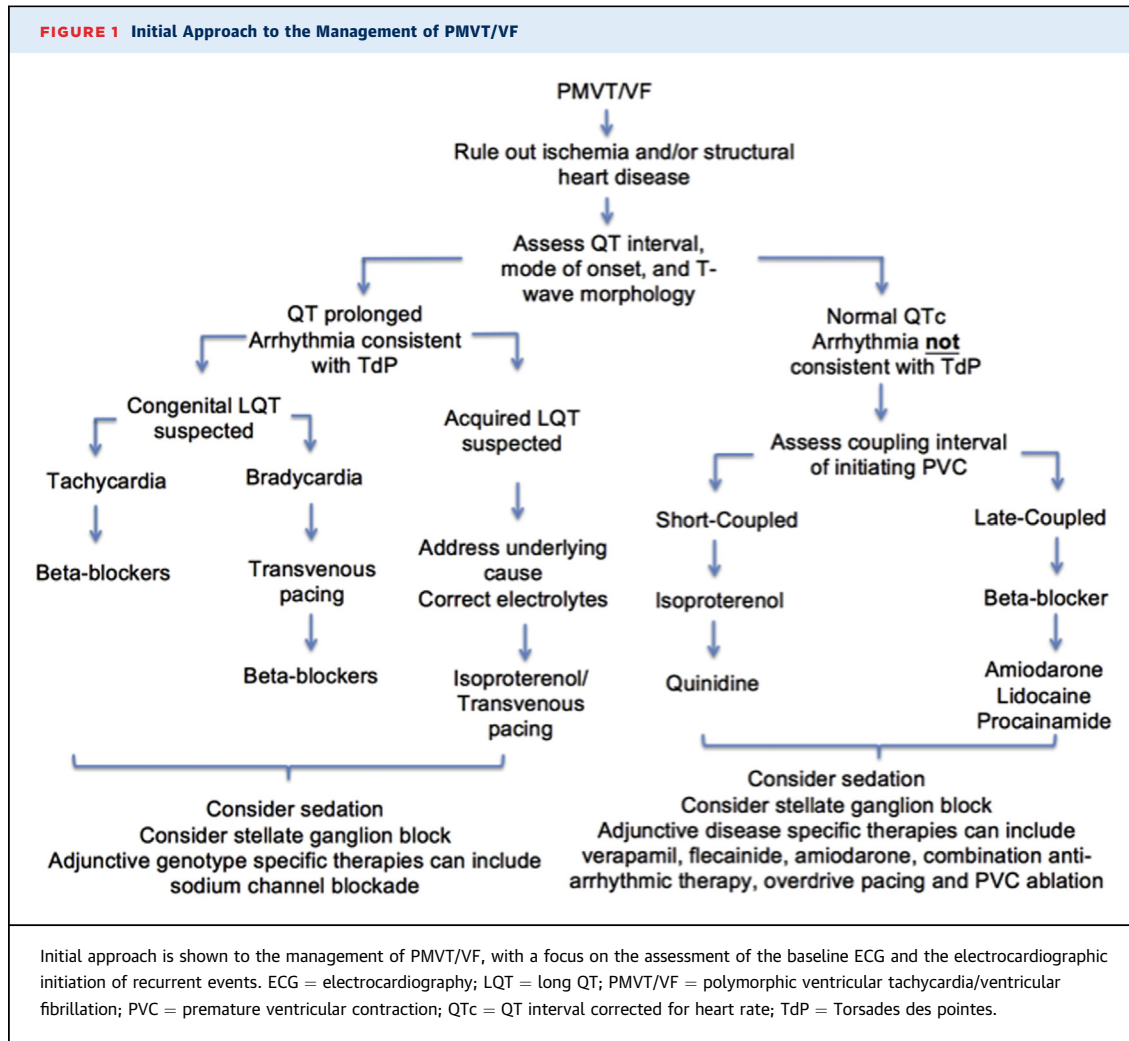
these estimates are likely to be lower in patients who go into cardiac arrest, as the QT interval is typically at its most prolonged around the time of the arrest (15).

THE QT INTERVAL

A prolonged QT interval is commonly seen in the setting of cardiac arrests and has limited diagnostic value in the acute phase, although persistent QT prolongation after the subacute phase can raise the clinical suspicion for LQTS. Acquired QT prolongation can be secondary to ischemia, electrolyte imbalances, intracranial processes including anoxic brain injury, cardioversion, medications, or temperature, all of which decrease the specificity for a diagnosis of LQTS (16). If reversible causes of QT prolongation are not present or are deemed unlikely and the initiation of recurrent electrical instability is consistent with Torsades des pointes (TdP) (see discussion below),

TABLE 1 Abbreviations

Condition	Abbreviation
Arrhythmogenic right ventricular cardiomyopathy	ARVC
Brugada syndrome	BrS
Catecholaminergic ventricular tachycardia	CPVT
Dilated cardiomyopathy	DCM
Early repolarization syndrome	ERS
Hypertrophic cardiomyopathy	HCM
Idiopathic ventricular fibrillation	IVF
Long QT syndrome	LQTS
Short coupled ventricular fibrillation	SC-VF
Short QT syndrome	SQTS



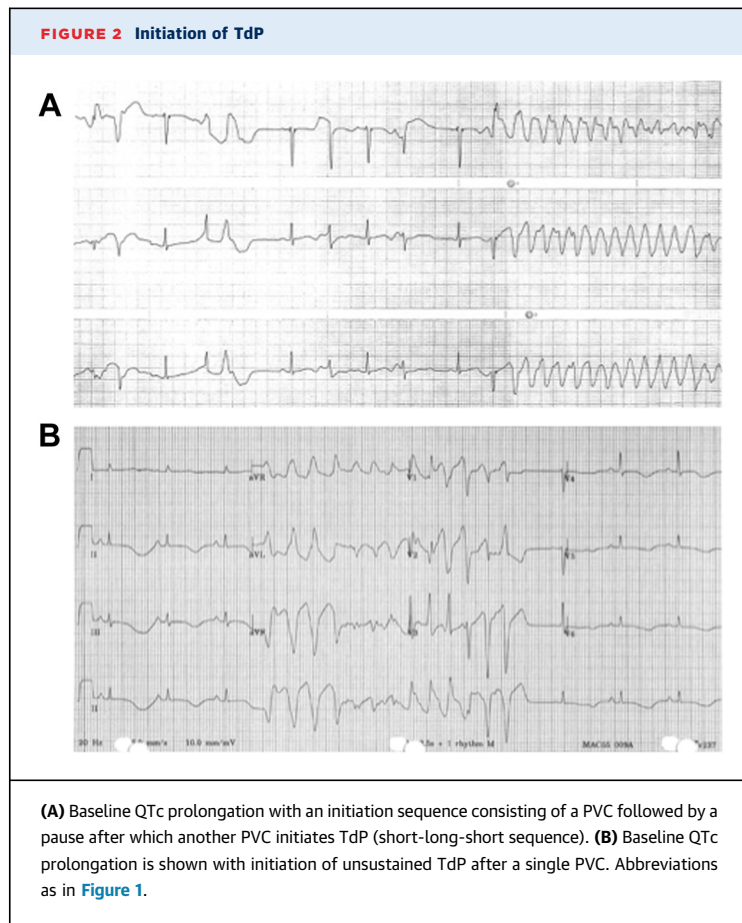
then the probability of an underlying inherited substrate is increased (Figure 2). In these cases, an evaluation of T-wave morphology may be helpful for distinguishing between acquired versus inherited LQTS and may suggest a specific genotype of inherited LQTS, which has potential management implications. Broad-based T waves suggest LQT1; low-amplitude, notched/biphasic T waves suggest LQT2; and prolonged ST-segments with peaked T waves suggest LQT3, although there is significant variability within each genotype and significant overlap among genotypes (17). T-wave alternans in polarity or amplitude signals a particularly high-risk electrical substrate and often precedes or follows a TdP event. Additionally, other abnormalities observed in the ECG may point to a specific genotype, if congenital LQTS is suspected. For example, unexplained pauses in sinus rhythm or conduction system

disease may suggest an underlying mutation in the *SCN5A* gene (LQT3).

A shortened QT interval of <360 ms or QTc <370 ms should raise suspicion of a short-QT syndrome (18). Approximately 5% of the normal population will have a QTc <370 ms, and multiple case series reports suggest an increased risk of VF is conferred when QTc is only modestly shortened (range: 360 to 370 ms) (19).

EARLY REPOLARIZATION

Persistent ST-segment or J-point elevation in the absence of other causes should raise suspicion of an inherited arrhythmia syndrome. A J-wave is defined as a positive deflection immediately following the QRS complex, either in the form of a notch or an ST-segment elevation (Figure 3). A J-wave “buried” in the R wave may manifest as J-point or ST-segment



elevation. The presence of the J-wave on a surface ECG is a reflection of transmural differences in the action potential (AP) notch or early repolarization. Epicardial APs have a pronounced AP notch in phase 1 mediated by a large magnitude of repolarizing, I_{to} , current, which is preferentially expressed in epicardial cardiomyocytes. The AP notch is followed by an AP dome, which is the result of sustained inward depolarizing currents causing net inward current (20). Conditions that decrease late or sustained inward current, such as sodium channel blockers, increased vagal tone, bradycardia, and ischemia will result in the loss of the dome of epicardial APs and accentuation of the J-wave on ECG. The presence of J waves suggests a similar underlying electrophysiologic substrate across a spectrum of congenital (e.g., early repolarization syndrome [ERS] or BrS) and acquired (transmural ischemia, hypothermia) J-wave syndromes.

BrS is diagnosed when there is ≥ 2 -mm ST-segment elevation with a type 1 pattern in ≥ 1 precordial lead (V_1 or V_2 positioned in the second, third, or fourth intercostal space). High-lead ECG testing (moving V_1

and V_2 to the second intercostal space) can increase the sensitivity of identifying a patient with BrS and can be performed in the acute setting (Figure 4) (21). ER is diagnosed if there is J-point elevation ≥ 1 mm in ≥ 2 contiguous inferior and/or lateral leads (22).

ER is common but should raise the suspicion of a malignant form in the context of unexplained cardiac arrest. ER has been identified in as many as 30% of patients in whom idiopathic VF (IVF) was diagnosed (23) but has also been identified as a cofactor for an increased risk of SCD when identified concomitantly with other inherited conditions including BrS, LQTS, short QT syndrome (SQTS), CPVT, and arrhythmogenic right ventricular cardiomyopathy (ARVC) (24).

CLUES TO INHERITED ARRHYTHMOGENIC CARDIOMYOPATHY: DEPOLARIZATION AND LATE REPOLARIZATION

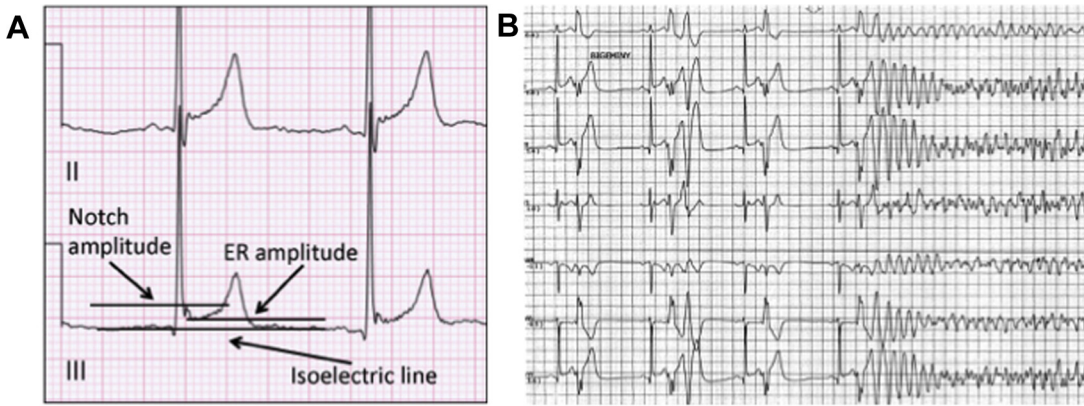
Fractionation of the QRS (fQRS) is a manifestation of ventricular conduction disturbance most commonly due to myocardial scar or infiltration that can be associated with dilated cardiomyopathies (DCM), cardiac sarcoidosis, and ARVC, and predicts risk (25). The presence of fQRS or other forms of conduction system disease are not typical features of the “primary electrical disorders,” in which BrS is the notable exception, where fQRS has been shown to predict occurrence of VF (26). Evidence of conduction system disease should alert the clinician to suspect an arrhythmogenic cardiomyopathy or infiltrative disorder, both of which may present in their early forms without apparent structural abnormalities on initial testing (27).

The presence of inverted T waves in the right precordial leads (V_1, V_2, V_3), particularly in the absence of a right bundle branch block, is a characteristic repolarization abnormality in ARVC. The appearance of epsilon waves, which are low-amplitude signals between the end of the QRS complex and the beginning of the T wave, is a major electrocardiographic criterion for the diagnosis of ARVC. In effect, these are macroscopic late potentials that typically represent advanced disease. Premature ventricular contractions (PVCs) and non-sustained ventricular tachycardia (NSVT) with left bundle branch block morphology and either a superior or inferior axis are common in ARVC.

PRESENTING ARRHYTHMIA AND MODE OF INITIATION

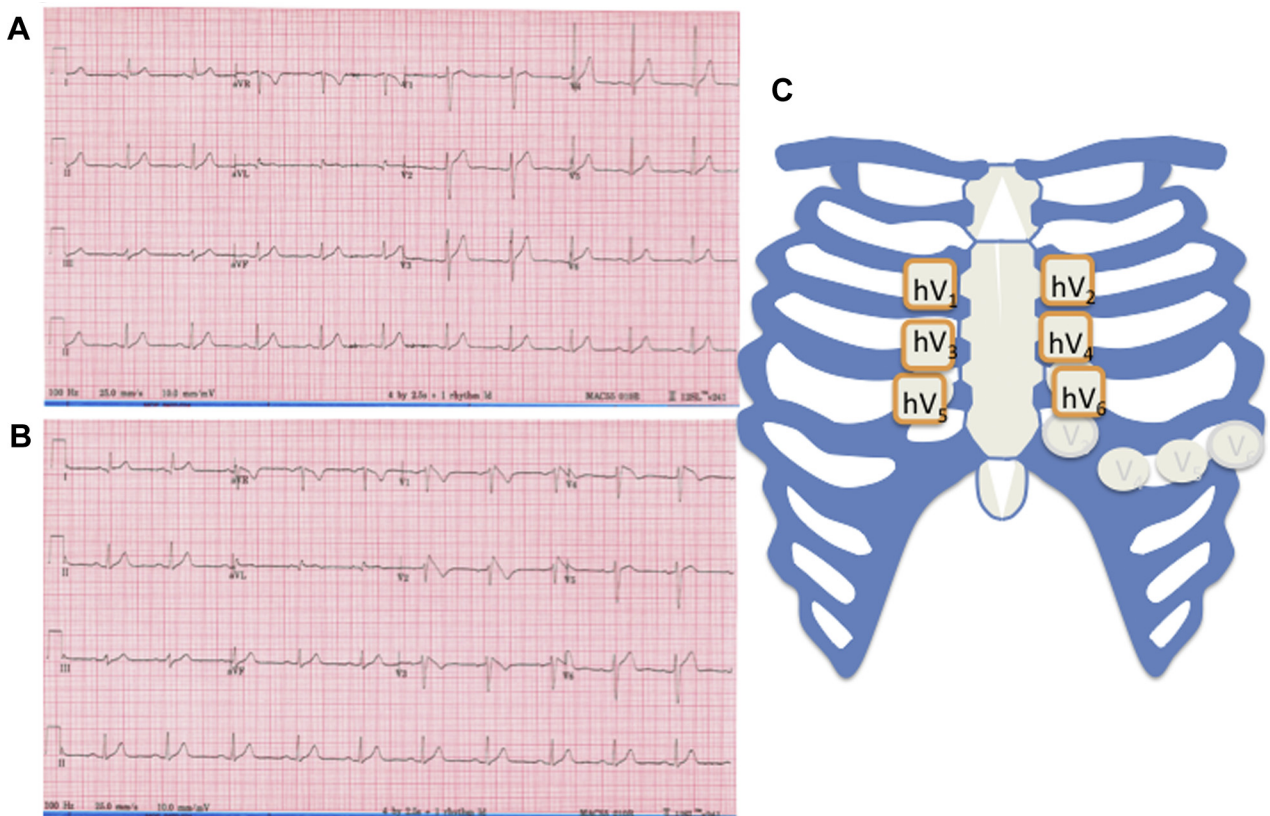
The differentiation among recurrent PMVT, monomorphic VT, and VF is critical to directing ongoing

FIGURE 3 Early Repolarization

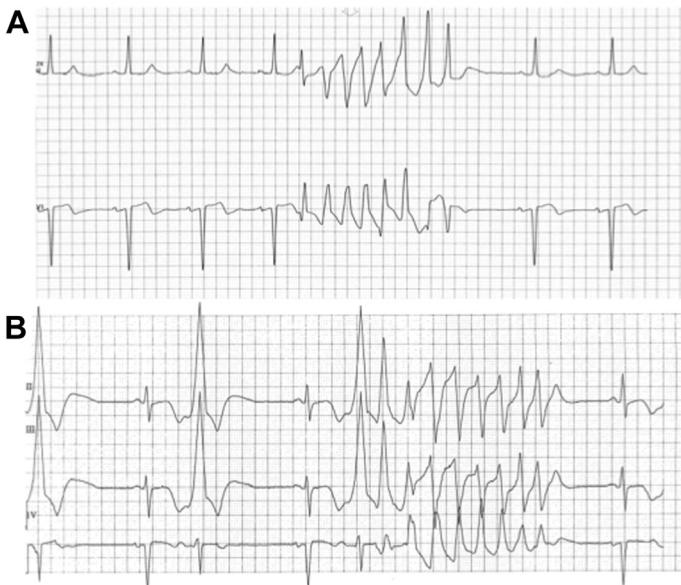

(A) ECG demonstrating measurement of 1 mm of ER with a notching morphology. (B) Initiation of VF with repeated short-coupled PVCs in the setting of baseline ER in the inferior leads. ER = early repolarization; other abbreviations as in Figure 1.

FIGURE 4 ECG Diagnosis of BrS



(A) Baseline ECG in a patient with recurrent nocturnal VF without evidence of BrS. (B) High-lead ECG taken concurrently on the same patient demonstrating a type 1 BrS ECG in the hV₁ and hV₂ leads. (C) Placement of electrodes is shown when performing a high-lead ECG. BrS = Brugada syndrome; VF = ventricular fibrillation; other abbreviations as in Figure 1.

FIGURE 5 Differentiating TdP from Other Forms of PMVT

(A) Nonsustained PMVT in a patient with normal QTc and single initiating PVC. **(B)** Nonsustained TdP in a patient with QTc prolongation and typical short-long-short initiation sequence. Abbreviations as in Figures 1 and 4.

management of recurrent unstable rhythms (Figure 5). In patients who have an ICD, interrogation is the preliminary diagnostic stem to determine the appropriateness of shock delivery, initiating rhythm, and degree of electrical instability. An important consideration in patients with ICDs is the detection programming, with a trend toward increasing detection intervals and possibly re-detection intervals over time in order to avoid unnecessary (non-life-saving) shocks for arrhythmia episodes, which may not be sustained (28). In the acute setting, ICD shock therapy may be inhibited in order to evaluate hemodynamic stability and, in some cases, to decrease the risk of pro-arrhythmia (9,29).

TdP is a form of PMVT that requires prolongation of the QT interval and enhanced transmural dispersion of repolarization (30). The appropriate differentiation between TdP and other forms of PMVT is important as TdP will guide future care and preclude the use of amiodarone, which could exacerbate TdP (31). TdP initiation is often associated with a short-long-short sequence, although other initiating sequences have been described in up to one-half of cases. Initiating PVCs are typically late-coupled and are believed to be caused by functional re-entry (32). TdP is often slower than other forms of PMVT, and there may be a precedent electrical prodrome of T-wave alternans or

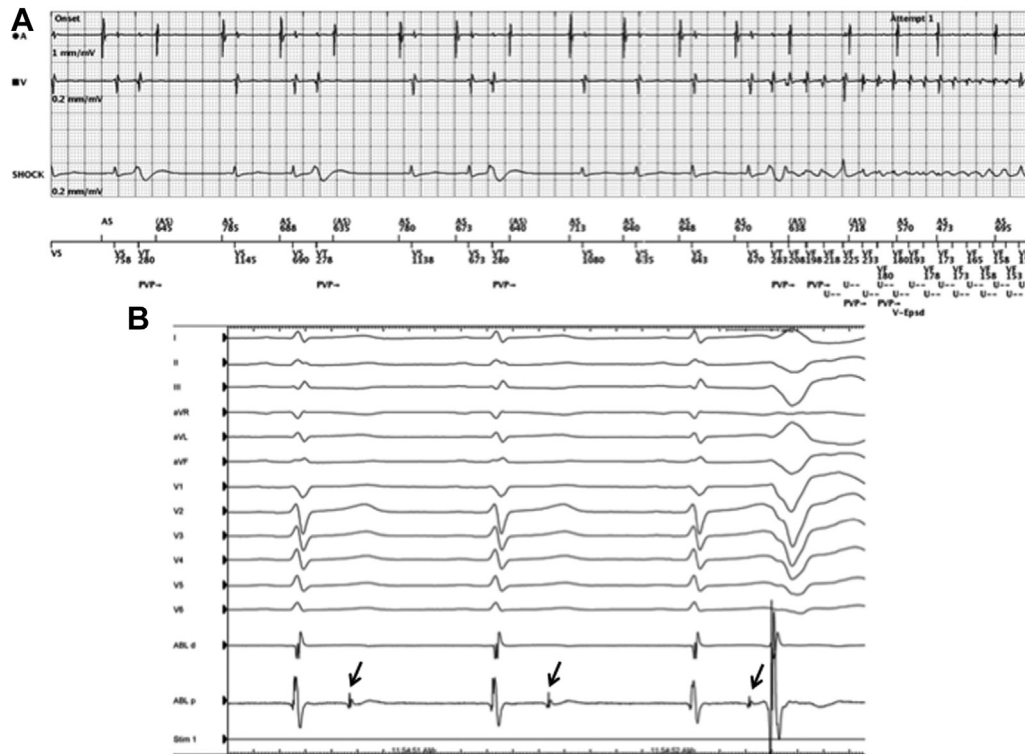
giant T-U waves, the latter being an ECG manifestation of early after depolarizations (EADs) (33).

The initial clinical approaches to a patient who presents with recurrent TdP, whether acquired (aLQTS) or congenital LQTS (cLQTS) is suspected, are relatively similar, although there are important differences. If there are reversible causes that can be addressed, resolution may prevent the need for other measures, including correcting hypomagnesemia (2-g intravenous bolus of magnesium sulfate over 2 to 3 min, followed by 2 to 4 mg/min infusion), targeting a normal potassium concentration (4.5 to 5 mmol/l) and treating profound hypocalcemia (<2.1 mmol/l), which can mimic cLQTS (34). Empiric supplementation with magnesium can be considered, as serum levels can poorly reflect intracellular concentrations.

If there is ongoing electrical instability after electrolyte correction, as shown by recurrent TdP, T-wave alternans, or a high burden of ventricular ectopy, the next step should be to increase the patient's heart rate. Increasing heart rate is an effective means of shortening action potential duration (APD) and QT interval and suppressing arrhythmias. Transvenous pacing is the preferred method in both aLQTS and cLQTS as beta-adrenergic stimulation may be pro-arrhythmic in some instances. Rates of up to 140 beats/min may be initially required to suppress arrhythmic storm but should subsequently be down-titrated to the lowest pacing rate required to suppress ventricular ectopy (35). The optimal pacing rate has not been clearly defined; however, in aLQTS, generally a rate exceeding 70 beats/min is adequate to suppress TdP overdrive (36). In patients with cLQTS, the rate required may be higher, >80 beats/min, and likely faster in children (37). Whereas atrial pacing is preferred from a physiologic standpoint, reliable temporary atrial pacing in the acute phase is more difficult to achieve technically.

In cases where recurrent shocks are necessary and transvenous pacing is not immediately available, isoproterenol infusion at 1 to 5 μ g/min may be considered if the patient is suspected of having aLQTS or is bradycardic and demonstrates that rhythm initiation is pause-dependent (38). Isoproterenol simultaneously increases repolarizing (I_{Ks}) current and depolarizing calcium current (I_{Ca-L}). The current predominantly affected will determine the effect on APD and QT interval. QT-prolonging medications most commonly have an impact on I_{Kr} current; therefore, augmentation of I_{Ks} with isoproterenol results in a net outward current and enhanced repolarization in aLQTS patients. Contrary to this, some inherited forms of LQTS (i.e., LQT1) are unable to recruit I_{Ks} current in

FIGURE 6 Patient With VF Storm Diagnosed by SC-VF



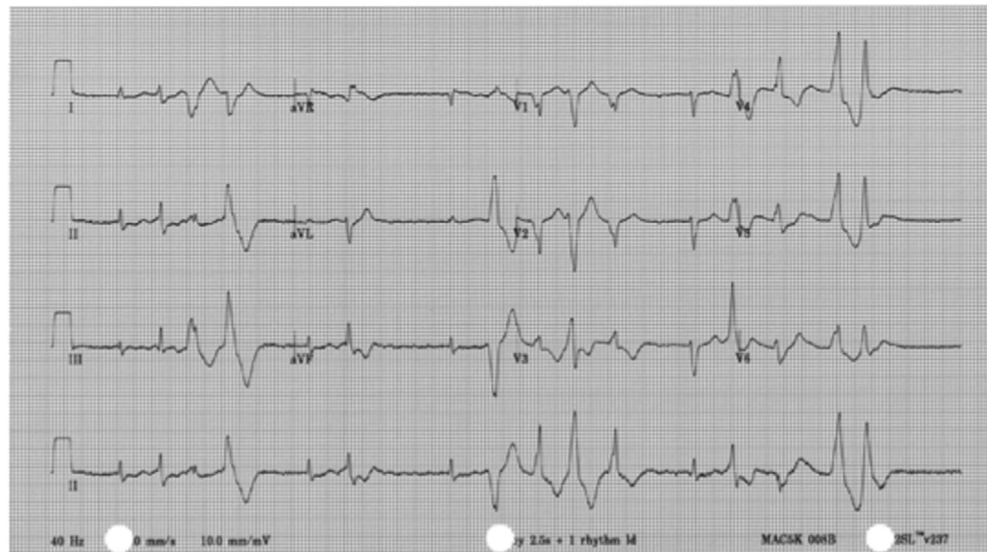(A) Interrogation of ICD demonstrates VF initiation with a short-coupled PVC. **(B)** Surface ECG and intracardiac electrograms from the ablation catheter in the same patient demonstrating a discrete local potential (**arrows**) on the proximal pole, representing repeated localized depolarization of the distal Purkinje system in the moderator band of the right ventricle that intermittently captures surrounding tissue, resulting in a PVC. Ablation at this site successfully suppressed PVC and VF. ICD = implantable cardioverter-defibrillator; SC-VF = short-coupled ventricular fibrillation; other abbreviations as in [Figure 1](#).

response to adrenergic stimuli (39), and net inward current results from calcium current augmentation. Electrophysiology studies in patients with cLQTS have demonstrated that isoproterenol increased APD, precipitated EADs, and increased dispersion of APD, whereas in the control group, isoproterenol shortened APD, was not associated with EADs, and did not effect APD dispersion (40). If isoproterenol is to be used in the setting of recurrent TdP, careful attention should be paid to the corrected QT interval to confirm appropriate shortening.

If a patient presents with recurrent TdP in the setting of sinus tachycardia and/or the initiating rhythm is not pause-dependent, the recurrent arrhythmia may be adrenergically mediated and require antiadrenergic therapy. This will be particularly important in patients with suspected cLQTS, in whom beta-blocker therapy can be considered as first-line management. Likewise, if a patient continues to have electrical instability despite

transvenous pacing at an adequate rate, beta-blocker therapy should be the next line of therapy. Either oral propranolol at a dosage of 2 to 4 mg/kg per day or nadolol at a dosage of 1 to 1.5 mg/kg per day is the most effective beta-blocker in the chronic setting, possibly because of their additional sustained sodium current-blocking properties (41), with a preference for nadolol (6). However, in the acute setting, a beta-blocker with a short half-life may be preferred, such as esmolol (intravenous loading dose of 0.5 mg/kg, followed by an infusion of 100 to 300 μ g/kg per min) (38). There is limited clinical experience with general anesthesia to decrease adrenergic drive in cLQTS patients with recurrent arrhythmia, although this is a relatively safe and low-risk option for refractory cases.

Although most genetically confirmed LQTS diagnoses are types 1 to 3, rare syndromic forms of cLQTS exist, such as Jervell and Lange-Nielsen syndrome (associated with congenital deafness),

FIGURE 7 Nonsustained Bidirectional or PMVT in a Patient With CPVT

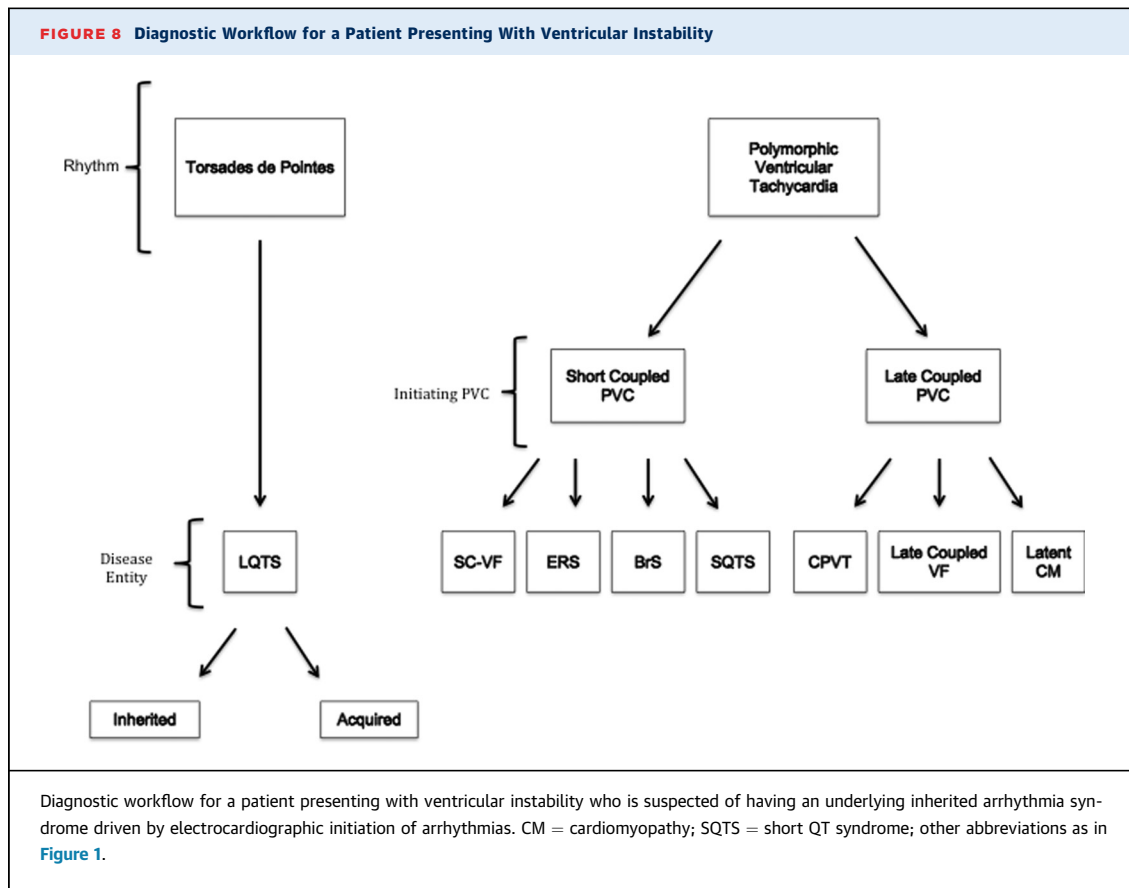
A final ancillary therapy in CPVT is left cardiac sympathetic denervation (101). Although data supporting sympathectomy in patients with frequent events, including ICD shocks, despite maximal medical therapy are mounting, a temporary SGB for acute VT/VF has not been investigated. In the critically ill CPVT patient with ongoing electrical storm, deep sedation and temporary sympathectomy may be considered. CPVT = catecholaminergic ventricular tachycardia; SGB = stellate ganglion block; VT = ventricular tachycardia; other abbreviations as in Figure 6.

Anderson-Tawil syndrome (associated with facial dysmorphisms and periodic paralysis), and Timothy syndrome (associated with syndactyly, cardiac malformations, and autism). The presence of these features can aid in accurate acute clinical diagnosis. ECG clues that point to a type of LQTS can help direct early management. LQT3 mutations are typically associated with an increase in persistent late sodium current; therefore, drugs with late Na current-blocking properties such as mexiletine, flecainide, ranolazine, and possibly lidocaine may be particularly effective, although evidence in the acute setting is limited (42,43). However, clinicians should watch carefully for electrocardiographic changes consistent with BrS, as there can be phenotypic and genotypic overlap. Until recently, there were concerns that (long-term) beta blockade could be harmful for LQTS3. However, beta-blockers appear to be safe and beneficial in all 3 forms of cLQTS (44).

In those patients with suspected cLQTS who present with malignant and refractory ventricular arrhythmia episodes, mechanical support may be the only option. In patients who are refractory to beta-blockers, antiarrhythmic therapy, and pacing, sympathetic denervation may be considered once the patient is stabilized (45). Stellate ganglion block

(SGB) may be performed at the bedside in emergent scenarios by an experienced anesthesiologist. To date, the largest systematic review examining the efficacy of SGB in electrical storm included only 38 patients who had a diverse set of disease substrates and 7 of 8 patients who demonstrated prolonged QT intervals exhibiting arrhythmia suppression (46). SGB is a temporizing measure that provides the patient with a bridge to more permanent solutions such as surgical cardiac sympathetic denervation or heart transplantation. A favorable response to SGB predicts that the patient will respond well to cardiac sympathetic denervation. Thoracic epidural anesthesia is another promising bedside intervention that has been successfully used to suppress ventricular storm in a case series of patients who predominantly had underlying structural heart disease (47,48).

PMVT, or VT with beat-to-beat variation in QRS morphology, is a potential manifestation of many inherited channelopathies as well as latent arrhythmogenic and infiltrative cardiomyopathies. In order to promptly delineate a particular disease entity, evaluation of features of the 12-lead ECG (reviewed above) and mode of initiation may be helpful, although ultimately, imaging may be required.



Short-coupled versus late-coupled PVCs that precipitate events can be used to characterize the underlying pathophysiology and inform management, as diseases within each category can be expected to have responses similar to a given therapy (Figure 1).

SHORT-COUPLED PVCs

Syndromes associated with short-coupled PVCs include the J-wave syndromes (BrS, ERS), SQTS, and SC-VF. The definition of a short-coupled PVC varies in studies but is generally defined as an R-R interval of <400 ms between the preceding QRS complex and subsequent PVC, often occurring before the peak of the T wave (49). In the absence of ischemia or hypothermia, recurrent VF preceded by pause-dependent J-wave accentuation, initiated by a very short-coupled PVC, is pathognomonic of a primary J-wave syndrome (Figure 3). J-wave syndromes can share common arrhythmogenic mechanisms and respond in fashion similar to that of pharmacologic management. J waves are dynamic and can respond to

various factors including sympathetic and parasympathetic states, cycle length, hypothermia, and medications. These and other factors are believed to alter the degree of repolarization dispersion and modulate the underlying substrate. At times of maximal dispersion of repolarization, phase 2 re-entry may occur whereby there is conduction from an AP dome at sites where it is maintained in sites where it is abolished, which ultimately precipitates re-entrant PMVT (50). Consistent with the concept of J-wave amplitude as a surrogate for substrate vulnerability, J waves typically increase in amplitude preceding a ventricular arrhythmia episode and subside after termination of the arrhythmia (51). Moreover, a subset of patients in whom IVF was diagnosed and had normal ECGs at baseline and no evidence of repolarization abnormalities developed dramatic J-wave changes during periods of electrical storm, thus implicating ERS (51). Notably J-wave amplitude is more useful to follow in an individual patient, as the absolute magnitude of J-point elevation has lower interpatient predictive value; although there are certain other ECG features including a horizontal/

descending ST-segment and inferior lead location that confer higher risk (52).

Therapies that restore the epicardial AP morphology ultimately reduce transmural dispersion of repolarization and result in suppression of arrhythmia. The amplitude of the J-wave may be a helpful ECG metric with which to determine the efficacy of therapy and predict likelihood of arrhythmia suppression, although there is minimal evidence to support this and no reliable provocation test to unmask its potential contribution to arrhythmogenesis. Isoproterenol therapy diminishes J waves and suppresses arrhythmia episodes likely through direct and indirect effects on L-type calcium current (I_{Ca-L}) and the transient outward potassium current (I_{to}), resulting in restoration of the epicardial AP dome (53). Isoproterenol therapy has demonstrated clear efficacy in the setting of electrical storm in patients with BrS (54-56) and ERS (51,57). Isoproterenol can be infused at rates of 1 to 5 $\mu\text{g}/\text{min}$ to target a heart rate of >120 beats/min. Quinidine's efficacy is felt to be related to its I_{to} blocking properties and is highly effective for suppressing VF in patients with BrS (54,58,59) as well as in ERS (51,60). Unfortunately, quinidine may be difficult to obtain in many jurisdictions in both the oral and intravenous forms due to worldwide production shortages (61). Invasive strategies may also be used in cases of drug refractoriness or intolerance. Both endocardial trigger elimination and epicardial substrate modification have been shown to be effective at reducing VF recurrence (62).

SQTS is a rare entity with minimal reported evidence to direct the acute management of arrhythmia episodes (63). Gain-of-function mutations in repolarizing potassium currents have been identified, resulting in enhanced ventricular repolarization and shortened QT intervals; however, most patients with the ultimate diagnosis of SQTS have an unidentified genetic basis (64). In clinical practice, a number of anti-arrhythmic drugs (AADs) have been used with mixed results for prophylactic treatment of arrhythmia and during the acute management of arrhythmia (65). Perhaps the best evidence exists for quinidine therapy, which has been shown to normalize the QT interval, T-wave morphology, and ventricular effective refractory period and has rendered VF noninducible in some cases (66). In the European short-QT registry, use of quinidine was associated with a reduction in arrhythmic events (64).

Isoproterenol was used in electrical storm in a case report; however, the patient also presented with ER pattern reflective of an overlapping or atypical presentation and the heterogeneous nature of patients described to date (67). Most arrhythmic events

in SQTS patients occur at rest or during sleep (64), suggesting that enhanced vagal tone is pro-arrhythmic and, thus, supports the observed efficacy of adrenergic therapy. However, this is at odds with the effects of isoproterenol observed in SQTS canine models, where adrenergic therapy promoted arrhythmic events (68).

Amiodarone has multichannel effects, with blockade of both the I_{kr} and I_{ks} currents, which have the potential to normalize repolarization in patients with SQTS with unknown genetic or pathophysiologic substrates. Unfortunately, amiodarone has demonstrated variable efficacy to date without sufficient evidence to support or guide its use.

Recently, the term "short-coupled ventricular fibrillation" (previously "short-coupled variant of TdP") has been used to describe a subset of IVF patients who share some common electrocardiographic features. These particular patients have a normal baseline ECG, and very short-coupled PVCs (often <300 ms) have been observed to initiate PMVT with a "Torsade-like" morphology (69). A genetic basis for this clinical entity has not yet been elucidated, and the electroanatomical substrate that is vulnerable to these very short-coupled PVCs is not well understood. The triggering PVCs have coupling intervals of 260 to 320 ms and typically have relatively narrow QRS morphologies (126 ± 17 ms) (70). Intracardiac mapping has demonstrated a preceding Purkinje potential (Figure 6), suggesting that the origin of the initiating PVCs is in the distal His-Purkinje system, although other focal sources have been identified (71). Abnormal calcium handling resulting in both EADs and DADs is the likely mechanism for these PVCs. Verapamil, an L-type calcium channel inhibitor, is known to suppress ectopic activity originating from the His-Purkinje system. There is evidence that verapamil suppresses ventricular arrhythmias in patients with SC-VF (69). More recently, there has been compelling evidence for quinidine in the chronic management of these patients (72,73).

Electrical storm is common in patients with SC-VF and has been reported in up to 15% of patients (57). Studies demonstrating the beneficial effect of isoproterenol in patients with SC-VF and electrical storm have for the most part been limited to patients who had an ER pattern on ECG at the time of presentation (51,57,60). In the setting of patients with SC-VF presenting with electrical storm, isoproterenol has been used effectively to suppress arrhythmia events (74,75). However, case series have also shown failure of isoproterenol in the setting of electrical storms (76,77). In patients not responsive to isoproterenol, intravenous verapamil may be an effective rescue therapy (77).

Mapping and catheter ablation of trigger PVCs from the His-Purkinje system or right ventricular outflow tract (RVOT) have demonstrated promising results and should be considered in selected patients with recurrent VF and in whom medical therapy has failed (71,78). The feasibility of eliminating the trigger PVCs has been demonstrated in several small studies with success rates of more than 80% and long-term survival without VF recurrence for up to nearly 8 years (79,80). Recurrent VF storm has been associated with an acute increase in PVC burden, suggesting that the trigger can remain dormant for intervening years between episodes (81). This also suggests that ablation must be undertaken around the period of VF recurrence in order to identify the culprit trigger or perhaps during a period when a dramatic increase in PVC burden is identified preceding a VF event.

LATE-COUPLED PVCs: CHANNELOPATHIES

Disease entities associated with late-coupled PVCs initiating ventricular arrhythmia events include CPVT and arrhythmogenic cardiomyopathies presenting without structural heart disease. In the absence of a formal definition for late-coupled PVCs, these can be described as PVCs which do not fulfill the aforementioned criteria for short-coupled PVCs, typically on the downslope or terminal portion of the T-wave and occurring in the absence of a prolonged QT interval.

CPVT is an especially deadly arrhythmia syndrome, with an earlier age of onset and a greater preponderance for breakthrough events, despite standard treatment (8). One of the main challenges in CPVT is its highly concealed nature, and often the only clue is an emotion- or exercise-triggered arrhythmic syncope, seizure, or sudden cardiac arrest in a young person (often childhood or adolescence). Mutations in genes controlling calcium handling in the sarcoplasmic reticulum lead to DADs, which clinically manifest as late-coupled polymorphic ventricular ectopy and/or bidirectional VT (82). Probably owing to the *catecholaminergic* triggering of DADs, patients can develop electrical storm during attempted resuscitation from cardiac arrest when treated with bolus epinephrine and repetitive defibrillations (either external or from an ICD) (9,29). As such, the standard algorithms used during a cardiac arrest may be harmful in the setting of CPVT.

Aside from rare case reports, there are no studies of the optimal management of acute arrhythmia episodes in CPVT. However, if this diagnosis is suspected, it is of paramount importance to reduce

all adrenergic stimuli to the heart. Electrical defibrillation, including ICD shock, should be used sparingly and certainly withheld in the absence of hemodynamically significant VT or VF, and in particular may be avoided or delayed for bidirectional VT, which is often self-limited (Figure 7). Beta-blockers are the cornerstone of acute and chronic treatment. Esmolol is an attractive choice given its intravenous formulation and short half-life. Successful management of VT has been described using intravenous propranolol (83).

A major success has been the recent discovery of the utility of flecainide in CPVT and its ultrarapid translation into clinical practice (84). Although flecainide has not demonstrated clear benefit in the acute setting, it may be reasonable to institute it in a case of CPVT storm.

LATE-COUPLED PVCs: ARRHYTHMOGENIC CARDIOMYOPATHIES

Ventricular arrhythmias may be the first presentation of an inherited cardiomyopathy such as ARVC, DCM, or hypertrophic cardiomyopathy. The ventricular arrhythmia may be monomorphic initially (approach to monomorphic VT is discussed below) with subsequent degeneration to PMVT/VF. However, PMVT/VF may be initiated directly by late-coupled PVCs. Another clue to an arrhythmogenic cardiomyopathy is an abnormal baseline ECG, such as those associated with variants in the *LMNA* gene, as many can be associated with conduction disease, increased or low voltage, or trademark repolarization changes (4). Pathogenic variants in genes typically associated with cardiomyopathies have been identified at molecular autopsy in patients with structurally normal hearts who have experienced SCD suggesting either a proarrhythmic phenotype without structural heart disease or latent cardiomyopathy which can present first with electrical disturbances (85). The initial treatment strategy for management of ventricular arrhythmia in patients with “subclinical” structural heart disease is similar and involves intravenous amiodarone and beta-blockade (86,87). Recently, a small study of patients with undifferentiated cardiomyopathy presenting with electrical storm, including a subset of patients with DCM (~17% of patients), demonstrated a significant reduction of ventricular arrhythmic events and ICD shocks in the use of intravenous amiodarone plus oral propranolol compared to intravenous amiodarone plus oral metoprolol (88). This likely reflects the importance of more potent adrenergic inhibition with a nonselective beta-blocker (propranolol).

MONOMORPHIC VENTRICULAR TACHYCARDIA

Patients who present with cardiac arrest in the context of monomorphic VT and have a normal echocardiogram on initial assessment should be strongly suspected of having an underlying “sub-clinical” cardiomyopathy. Subtle structural heart disease may not be detected with echocardiography or during invasive ventriculography, and patients should go on to have further imaging such as cardiac magnetic resonance or positron emission tomography, which have higher sensitivities for latent and infiltrative cardiomyopathies (89,90).

Monomorphic VT that is hemodynamically unstable and results in cardiac arrest or electrical storm in the context of a structurally normal heart outside of the aforementioned latent or arrhythmogenic cardiomyopathies is rare. It is important to note, however, that, although idiopathic VT arising from the outflow tract or other regions of the heart typically have a benign prognosis in an otherwise normal heart, if a susceptible electroanatomical substrate coexists, malignant arrhythmias may develop. Benign idiopathic tachycardias are known to coexist in patients with primary inherited arrhythmia events, and outflow tract PVCs have been observed to trigger polymorphic VT in CPVT, BrS, LQTS, and IVF (91,92). Whether this represents an overlap of rare and common conditions or a distinct predisposition to ventricular ectopy in some patients with inherited arrhythmia syndromes is unknown. One small study identified patients with PVC-induced PMVT/VF that would not typically be considered short-coupled. Noda et al. (92) described a cohort of 16 patients without known structural heart disease who did not develop structural heart disease in the follow-up period of nearly 5 years. These patients had RVOT tachycardia but experienced episodes of PMVT/VF initiated by PVCs arising from the RVOT, with mean coupling intervals of 409 ms. This has been described as “malignant” RVOT VT. These patients responded well to targeted ablation (92). Finally, cases of bundle branch reentry tachycardia, previously thought to occur only in cardiomyopathies with extensive conduction system disease, presenting with VT or cardiac arrest, have been described in patients with normal biventricular function in whom a genetic culprit in the *SCN5A* gene has been identified (93).

In patients with ARVC, arrhythmia usually arises from the RV and may have multiple morphologies, although biventricular involvement is increasingly identified. The majority of appropriate ICD therapies are for sustained, rapid monomorphic VT; however,

there are subsets of patients who receive therapy for PMVT as well (94). Amiodarone therapy may have superior efficacy than beta-blockade or sotalol for suppression of ventricular arrhythmias (95), but any of these options can be considered first-line therapy. Combination therapies may be necessary in patients with recurrent arrhythmia episodes receiving monotherapy. Combination therapies with established efficacy include, first, amiodarone with beta-blockers (96) and, second, Class I agents in addition to amiodarone/sotalol (97). In particular, combination therapy with sotalol/metoprolol and flecainide has demonstrated efficacy in patients not responding to single-agent therapy or even catheter ablation (98). Endoepicardial ablation may be useful to reduce arrhythmic burden (99). Bilateral sympathectomy was performed successfully in a patient with arrhythmia refractory to maximal medical therapy and who had undergone repeated ablation procedures (100).

CONCLUSIONS

A subset of patients presenting with malignant ventricular arrhythmias have no identifiable structural or ischemic heart disease at the time of presentation. In these cases, an underlying inherited arrhythmia syndrome should be strongly considered. In the emergency setting, clinicians should focus on clinical and electrocardiographic clues to help guide management. Focused analysis of the baseline ECG and then careful interrogation of the mode of onset can help facilitate a working diagnosis which will inform the initial management of patients in storm (Figure 8). After ensuring appropriate monitoring and resuscitation equipment is available, the next most critical step in the emergent decision algorithm is the first line of medications employed, with careful reassessment based on clinical response. Equally important is the avoidance of medications, particularly long-acting medications such as amiodarone, which can exacerbate the electrical instability in the short term. The acute management of electrical storm in a patient with a *suspected* but undiagnosed primary arrhythmia disorder or a patient with an established diagnosis presenting with recurrent events, which may or may not be stereotypical, poses a significant challenge for emergency care providers and should involve emergent consultation with local expertise.

ADDRESS FOR CORRESPONDENCE: Dr. Zachary Laksman, Heart Rhythm Vancouver, 211-1033 Davie Street, Vancouver, British Columbia V6E 1M7, Canada. E-mail: zlaksman@mail.ubc.ca.

REFERENCES

1. Pathak RK, Sanders P, Deo R. Primary prevention implantable cardioverter-defibrillator and opportunities for sudden cardiac death risk assessment in non-ischaemic cardiomyopathy. *Eur Heart J* 2018;39:2859-66.
2. Herman ARM, Cheung C, Gerull B, et al. outcome of apparently unexplained cardiac arrest: results from investigation and follow-up of the prospective cardiac arrest survivors with preserved ejection fraction registry. *Circ Arrhythm Electrophysiol* 2016;9:e003619.
3. Mozaffarian D, Benjamin EJ, Go AS, et al., for the American Heart Association Statistics Committee, Stroke Statistics Subcommittee. Heart Disease and Stroke Statistics-2016. Update: a report from the American Heart Association. *Circulation* 2016;133:38-60.
4. Laksman Z, Dulay D, Gollob MH, Skanes AC, Krahn AD. Evolution of a genetic diagnosis. *Clin Genet* 2014;86:580-4.
5. Steinberg C, Padfield GJ, Champagne J, et al. Cardiac abnormalities in first-degree relatives of unexplained cardiac arrest victims: a report from the Cardiac Arrest Survivors With Preserved Ejection Fraction Registry. *Circ Arrhythm Electrophysiol* 2016;9:e004274.
6. Mazzanti A, Maragna R, Vacanti G, et al. Interplay between genetic substrate, qtc duration, and arrhythmia risk in patients with long QT syndrome. *J Am Coll Cardiol* 2018;71:1663-71.
7. Milman A, Andorin A, Gourraud J-B, et al. Age of first arrhythmic event in brugada syndrome: data from the SABRUS (Survey on Arrhythmic Events in Brugada Syndrome) in 678 Patients. *Circ Arrhythm Electrophysiol* 2017;10:e005222.
8. Roston TM, Vinocur JM, Maginot KR, et al. Catecholaminergic polymorphic ventricular tachycardia in children: analysis of therapeutic strategies and outcomes from an international multicenter registry. *Circ Arrhythm Electrophysiol* 2015;8:633-42.
9. Roston TM, Jones K, Hawkins NM, et al. Implantable cardioverter-defibrillator use in catecholaminergic polymorphic ventricular tachycardia: a systematic review. *Heart Rhythm* 2018;15:1791-9.
10. Bella Della P, Baratto F, Tsiachris D, et al. Management of ventricular tachycardia in the setting of a dedicated unit for the treatment of complex ventricular arrhythmias: long-term outcome after ablation. *Circulation* 2013;127:1359-68.
11. Tang PT, Do DH, Li A, Boyle NG. Team management of the ventricular tachycardia patient. *Arrhythm Electrophysiol Rev* 2018;7:238-46.
12. Shah AJ, Hocini M, Denis A, et al. Polymorphic ventricular tachycardia/ventricular fibrillation and sudden cardiac death in the normal heart. *Card Electrophysiol Clin* 2016;8:581-91.
13. Modi S, Krahn AD. Sudden cardiac arrest without overt heart disease. *Circulation* 2011;123:2994-3008.
14. Waldmann V, Bougouin W, Karam N, et al., for the Paris-SDEC investigators. Characteristics and clinical assessment of unexplained sudden cardiac arrest in the real-world setting: focus on idiopathic ventricular fibrillation. *Eur Heart J* 2018;39:1981-7.
15. Conti CR. Inherited long QT syndrome: phenotype and therapy to use and avoid. *Clin Cardiol* 2006;29:429-30.
16. Laksman ZWM, Krahn AD. Fast and spurious: correcting the QT interval. *Heart Rhythm* 2016;13:536-7.
17. Zareba W. Genotype-specific ECG patterns in long QT syndrome. *J Electrocardiol* 2006;39:S101-6.
18. Viskin S. The QT interval: too long, too short or just right. *Heart Rhythm* 2009;6:711-5.
19. Viskin S, Zeltser D, Ish-Shalom M, et al. Is idiopathic ventricular fibrillation a short QT syndrome? Comparison of QT intervals of patients with idiopathic ventricular fibrillation and healthy controls. *Heart Rhythm* 2004;1:587-91.
20. Yan GX, Antzelevitch C. Cellular basis for the electrocardiographic J wave. *Circulation* 1996;93:372-9.
21. Antzelevitch C, Yan G-X, Ackerman MJ, et al. J-wave syndromes expert consensus conference report: emerging concepts and gaps in knowledge. *J Arrhythm* 2016;32:315-39.
22. Priori SG, Wilde AA, Horie M, et al. HRS/EHRA/APHSR expert consensus statement on the diagnosis and management of patients with inherited primary arrhythmia syndromes: document endorsed by HRS, EHRA, and APHSR in May 2013 and by ACCF, AHA, PACES, and AEPC in June 2013. *Heart Rhythm* 2013;10:1932-63.
23. Haïssaguerre M, Derval N, Sacher F, et al. Sudden cardiac arrest associated with early repolarization. *N Engl J Med* 2008;358:2016-23.
24. Obeyesekere MN, Krahn AD. Early repolarisation—what should the clinician do? *Arrhythm Electrophysiol Rev* 2015;4:96-9.
25. Sha J, Zhang S, Tang M, Chen K, Zhao X, Wang F. Fragmented QRS is associated with all-cause mortality and ventricular arrhythmias in patient with idiopathic dilated cardiomyopathy. *Ann Noninvasive Electrocardiol* 2011;16:270-5.
26. Morita H, Kusano KF, Miura D, et al. Fragmented QRS as a marker of conduction abnormality and a predictor of prognosis of Brugada syndrome. *Circulation* 2008;118:1697-704.
27. Cheng J, Morales A, Siegfried JD, et al. SCN5A rare variants in familial dilated cardiomyopathy decrease peak sodium current depending on the common polymorphism H558R and common splice variant Q1077del. *Clin Transl Sci* 2010;3:287-94.
28. Sedláček K, Ruwald A-C, Kutýřa V, et al., for the MADIT-RIT Investigators. The effect of ICD programming on inappropriate and appropriate ICD Therapies in ischemic and nonischemic cardiomyopathy: the MADIT-RIT trial. *J Cardiovasc Electrophysiol* 2015;26:424-33.
29. Miyake CY, Webster G, Czosek RJ, et al. Efficacy of implantable cardioverter defibrillators in young patients with catecholaminergic polymorphic ventricular tachycardia: success depends on substrate. *Circ Arrhythm Electrophysiol* 2013;6:579-87.
30. Lankipalli RS, Zhu T, Guo D, Yan G-X. Mechanisms underlying arrhythmogenesis in long QT syndrome. *J Electrocardiol* 2005;38:69-73.
31. Digby G, Machaalany J, Malik P, Methot M, Simpson CS, Redfearn D, Baranchuk A. Multifactorial QT interval prolongation. *Cardiol J* 2010;17:184-8.
32. Noda T, Shimizu W, Satomi K, et al. Classification and mechanism of Torsade de Pointes initiation in patients with congenital long QT syndrome. *Eur Heart J* 2004;25:2149-54.
33. Jackman WM, Friday KJ, Anderson JL, Aliot EM, Clark M, Lazzara R. The long QT syndromes: a critical review, new clinical observations and a unifying hypothesis. *Prog Cardiovasc Dis* 1988;31:115-72.
34. Yazdan-Ashoori P, Digby G, Baranchuk A. Failure to treat Torsades de pointes. *Cardiol Res* 2012;3:34-6.
35. Viskin S. Long QT syndromes and torsade de pointes. *J Cardiovasc Electrophysiol* 1999;35:1625-33.
36. Pinski SL, Eguía LE, Trohman RG. What is the minimal pacing rate that prevents torsades de pointes? Insights from patients with permanent pacemakers. *Pacing Clin Electrophysiol* 2002;25:1612-5.
37. Viskin S. Cardiac pacing in the long QT syndrome: review of available data and practical recommendations. *J Cardiovasc Electrophysiol* 2000;11:593-600.
38. Shah M, Carter C. Long QT syndrome: a therapeutic challenge. *Ann Pediatr Cardiol* 2008;1:18-26.
39. Ackerman MJ, Khositseth A, Tester DJ, Hejlik JB, Shen W-K, Porter C-BJ. Epinephrine-induced QT interval prolongation: a gene-specific paradoxical response in congenital long QT syndrome. *Mayo Clin Proc* 2002;77:413-21.
40. Shimizu W, Ohe T, Kurita T, et al. Early afterdepolarizations induced by isoproterenol in patients with congenital long QT syndrome. *Circulation* 1991;84:1915-23.
41. Chockalingam P, Crotti L, Girardengo G, et al. Not all beta-blockers are equal in the management of long QT syndrome types 1 and 2: higher recurrence of events under metoprolol. *J Am Coll Cardiol* 2012;60:2092-9.
42. Chorin E, Taub R, Medina A, Flint N, Viskin S, Benhorin J. Long-term flecainide therapy in type 3 long QT syndrome. *Europace* 2018;20:370-6.
43. Giudicessi JR, Ackerman MJ. Genotype- and phenotype-guided management of congenital long QT syndrome. *Curr Probl Cardiol* 2013;38:417-55.
44. Wilde AAM, Moss AJ, Kaufman ES, et al. Clinical aspects of type 3 long-QT syndrome: an

- international multicenter study. *Circulation* 2016;134:872-82.
45. Cho Y. Left cardiac sympathetic denervation: an important treatment option for patients with hereditary ventricular arrhythmias. *J Arrhythm* 2016;32:340-3.
 46. Meng L, Tseng C-H, Shivkumar K, Ajjjola O. Efficacy of stellate ganglion blockade in managing electrical storm: a systematic review. *J Am Coll Cardiol EP* 2017;3:942-9.
 47. Bradfield JS, Ajjjola OA, Vaseghi M, Shivkumar K. Mechanisms and management of refractory ventricular arrhythmias in the age of autonomic modulation. *Heart Rhythm* 2018;15:1252-60.
 48. Do DH, Bradfield J, Ajjjola OA, et al. Thoracic epidural anesthesia can be effective for the short-term management of ventricular tachycardia storm. *J Am Heart Assoc* 2017;6. pii:e007080.
 49. Thanavaro S, Kleiger RE, Miller JP, Province MA, Friedman E, Oliver GC. Coupling interval and types of ventricular ectopic activity associated with ventricular runs. *Am Heart J* 1983;106:484-91.
 50. Antzelevitch C. In vivo human demonstration of phase 2 reentry. *Heart Rhythm* 2005;2:804-6.
 51. Aizawa Y, Chinushi M, Hasegawa K, et al. Electrical storm in idiopathic ventricular fibrillation is associated with early repolarization. *J Am Coll Cardiol* 2013;62:1015-9.
 52. Adler A, Gollob MH. A practical guide to early repolarization. *Curr Opin Cardiol* 2015;30:8-16.
 53. Roten L, Derval N, Sacher F, et al. Heterogeneous response of J-wave syndromes to beta-adrenergic stimulation. *Heart Rhythm* 2012;9:1970-6.
 54. Jongman JK, Jekes-Bruin N, Ramdat Misier AR, et al. Electrical storms in Brugada syndrome successfully treated with isoproterenol infusion and quinidine orally. *Neth Heart J* 2007;15:151-5.
 55. Watanabe A, Fukushima Kusano K, Morita H, et al. Low-dose isoproterenol for repetitive ventricular arrhythmia in patients with Brugada syndrome. *Eur Heart J* 2006;27:1579-83.
 56. Maury P, Couderc P, Delay M, Boveda S, Brugada J. Electrical storm in Brugada syndrome successfully treated using isoprenaline. *Europace* 2004;6:130-3.
 57. Haïssaguerre M, Sacher F, Nogami A, et al. Characteristics of recurrent ventricular fibrillation associated with inferolateral early repolarization role of drug therapy. *J Am Coll Cardiol* 2009;53:612-9.
 58. Mok N-S, Chan N-Y, Chiu AC-S. Successful use of quinidine in treatment of electrical storm in Brugada syndrome. *Pacing Clin Electrophysiol* 2004;27:821-3.
 59. Bettiol K, Gianfranchi L, Scarfò S, Pacchioni F, Pedaci M, Alboni P. Successful treatment of electrical storm with oral quinidine in Brugada syndrome. *Ital Heart J* 2005;6:601-2.
 60. Chinushi M, Hasegawa K, Iijima K, Furushima H, Izumi D, Sato A, Aizawa Y. Characteristics of J wave-associated idiopathic ventricular fibrillation: role of drugs. *Pacing Clin Electrophysiol* 2012;35:e226-30.
 61. Viskin S, Wilde AAM, Guevara-Valdivia ME, et al. Quinidine, a life-saving medication for Brugada syndrome, is inaccessible in many countries. *J Am Coll Cardiol* 2013;61:2383-7.
 62. Talib AK, Takagi M, Shimane A, et al. Efficacy of endocardial ablation of drug-resistant ventricular fibrillation in Brugada syndrome. *Circ Arrhythm Electrophysiol* 2018;11:e005631.
 63. Gollob MH, Redpath CJ, Roberts JD. The short QT syndrome: proposed diagnostic criteria. *J Am Coll Cardiol* 2011;57:802-12.
 64. Giustetto C, Schimpf R, Mazzanti A, et al. Long-term follow-up of patients with short QT syndrome. *J Am Coll Cardiol* 2011;58:587-95.
 65. Rudic B, Schimpf R, Borggreffe M. Short QT syndrome - review of diagnosis and treatment. *Arrhythm Electrophysiol Rev* 2014;3:76-9.
 66. Gaita F, Giustetto C, Bianchi F, et al. Short QT syndrome: pharmacological treatment. *J Am Coll Cardiol* 2004;43:1494-9.
 67. Bun S-S, Maury P, Giustetto C, Deharo J-C. Electrical storm in short-QT syndrome successfully treated with Isoproterenol. *J Cardiovasc Electrophysiol* 2012;23:1028-30.
 68. Extramiana F, Antzelevitch C. Amplified transmural dispersion of repolarization as the basis for arrhythmogenesis in a canine ventricular-wedge model of short-QT syndrome. *Circulation* 2004;110:3661-6.
 69. Leenhardt A, Glaser E, Burguera M, Nürnberg M, Maison-Blanche P, Coumel P. Short-coupled variant of torsade de pointes. A new electrocardiographic entity in the spectrum of idiopathic ventricular tachyarrhythmias. *Circulation* 1994;89:206-15.
 70. Haïssaguerre M, Shoda M, Jaïs P, et al. Mapping and ablation of idiopathic ventricular fibrillation. *Circulation* 2002;106:962-7.
 71. Nogami A. Mapping and ablating ventricular premature contractions that trigger ventricular fibrillation: trigger elimination and substrate modification. *J Cardiovasc Electrophysiol* 2015;26:110-5.
 72. Belhassen B, Viskin S, Fish R, Glick A, Setbon I, Eldar M. Effects of electrophysiologic-guided therapy with class IA antiarrhythmic drugs on the long-term outcome of patients with idiopathic ventricular fibrillation with or without the Brugada syndrome. *J Cardiovasc Electrophysiol* 1999;10:1301-12.
 73. Belhassen B, Glick A, Viskin S. Excellent long-term reproducibility of the electrophysiologic efficacy of quinidine in patients with idiopathic ventricular fibrillation and Brugada syndrome. *Pacing Clin Electrophysiol* 2009;32:294-301.
 74. Godinho AR, Frutuoso C, Vasconcelos M, et al. Arrhythmic storm: short-coupled variant torsade de pointes. *Rev Port Cardiol* 2016;35:307. e1-5.
 75. Chiladakis JA, Spiroulas G, Koutsogiannis N, Zagli F, Alexopoulos D. Short-coupled variant of Torsade de Pointes as a cause of electrical storm and aborted sudden cardiac death: insights into mechanism and treatment. *Hellenic J Cardiol* 2008;49:360-4.
 76. Chokr MO, Darrieux FCDC, Hardy CA, et al. Short-coupled variant of "torsades de pointes" and polymorphic ventricular tachycardia. *Arq Bras Cardiol* 2014;102:e60-4.
 77. Burrows K, Fox J, Biblo LA, Roth JA. Pregnancy and short-coupled torsades de pointes. *Pacing Clin Electrophysiol* 2013;36:e77-9.
 78. Nogami A, Naito S, Tada H, et al. Verapamil-sensitive left anterior fascicular ventricular tachycardia: results of radiofrequency ablation in six patients. *J Cardiovasc Electrophysiol* 1998;9:1269-78.
 79. Van Herendael H, Zado ES, Haqqani H, et al. Catheter ablation of ventricular fibrillation: importance of left ventricular outflow tract and papillary muscle triggers. *Heart Rhythm* 2014;11:566-73.
 80. Knecht S, Sacher F, Wright M, et al. Long-term follow-up of idiopathic ventricular fibrillation ablation: a multicenter study. *J Am Coll Cardiol* 2009;54:522-8.
 81. Mellor G, Steinberg C, Laksman Z, Deyell MW. Short-coupled ventricular fibrillation. *J Cardiovasc Electrophysiol* 2016;27:1236-7.
 82. Priori SG, Napolitano C, Tiso N, et al. Mutations in the cardiac ryanodine receptor gene (hRyR2) underlie catecholaminergic polymorphic ventricular tachycardia. *Circulation* 2001;103:196-200.
 83. De Rosa G, Delogu AB, Piastra M, Chiaretti A, Bloise R, Priori SG. Catecholaminergic polymorphic ventricular tachycardia: successful emergency treatment with intravenous propranolol. *Pediatr Emerg Care* 2004;20:175-7.
 84. Kannankeril PJ, Moore JP, Cerrone M, et al. Efficacy of flecainide in the treatment of catecholaminergic polymorphic ventricular tachycardia: a randomized clinical trial. *JAMA Cardiol* 2017;2:759-66.
 85. Bagnall RD, Weintraub RG, Ingles J, et al. A prospective study of sudden cardiac death among children and young adults. *N Engl J Med* 2016;374:2441-52.
 86. Priori SG, Blomström-Lundqvist C, Mazzanti A, et al. 2015 ESC guidelines for the management of patients with ventricular arrhythmias and the prevention of sudden cardiac death: the Task Force for the Management of Patients with Ventricular Arrhythmias and the Prevention of Sudden Cardiac Death of the European Society of Cardiology (ESC). Endorsed by: Association for European Paediatric and Congenital Cardiology (AEPC). *Eur Heart J* 2015;36. 2793-67.
 87. Al-Khatib SM, Stevenson WG, Ackerman MJ, et al. 2017 AHA/ACC/HRS guideline for management of patients with ventricular arrhythmias and the prevention of sudden cardiac death: executive summary: a report of the American College of Cardiology/American Heart Association Task Force on Clinical Practice Guidelines and the Heart Rhythm Society. *J Am Coll Cardiol* 2018;72:1677-749.
 88. Chatzidou S, Kontogiannis C, Tsilimigras DI, et al. Propranolol versus metoprolol for treatment of electrical storm in patients with implantable cardioverter-defibrillator. *J Am Coll Cardiol* 2018;71:1897-906.

- 89.** Wu KC. Sudden cardiac death substrate imaged by magnetic resonance imaging: from investigational tool to clinical applications. *Circ Cardiovasc Imaging* 2017;10. e005461.
- 90.** Vettiyil B, Gupta N, Kumar R. Positron emission tomography imaging in sarcoidosis. *World J Nucl Med* 2013;12:82-6.
- 91.** Viskin S, Rosso R, Rogowski O, Belhassen B. The "short-coupled" variant of right ventricular outflow ventricular tachycardia: a not-so-benign form of benign ventricular tachycardia? *J Cardiovasc Electrophysiol* 2005;16:912-6.
- 92.** Noda T, Shimizu W, Taguchi A, et al. Malignant entity of idiopathic ventricular fibrillation and polymorphic ventricular tachycardia initiated by premature extrasystoles originating from the right ventricular outflow tract. *J Am Coll Cardiol* 2005;46:1288-94.
- 93.** Roberts JD, Gollob MH, Young C, et al. Bundle branch re-entrant ventricular tachycardia: novel genetic mechanisms in a life-threatening arrhythmia. *J Am Coll Cardiol EP* 2017;3:276-88.
- 94.** Link MS, Laidlaw D, Polonsky B, et al. Ventricular arrhythmias in the North American multidisciplinary study of ARVC: predictors, characteristics, and treatment. *J Am Coll Cardiol* 2014;64:119-25.
- 95.** Marcus GM, Glidden DV, Polonsky B, et al., for the Multidisciplinary Study of Right Ventricular Dysplasia Investigators. Efficacy of antiarrhythmic drugs in arrhythmogenic right ventricular cardiomyopathy: a report from the North American ARVC Registry. *J Am Coll Cardiol* 2009;54:609-15.
- 96.** Tonet J, Frank R, Fontaine G, Grosgeat Y. [Efficacy of the combination of low doses of beta-blockers and amiodarone in the treatment of refractory ventricular tachycardia]. *Arch Mal Coeur Vaiss* 1989;82:1511-7.
- 97.** Wichter T, Borggrete M, Haverkamp W, Chen X, Breithardt G. Efficacy of antiarrhythmic drugs in patients with arrhythmogenic right ventricular disease. Results in patients with inducible and noninducible ventricular tachycardia. *Circulation* 1992;86:29-37.
- 98.** Ermakov S, Gerstenfeld EP, Svetlichnaya Y, Scheinman MM. Use of flecainide in combination antiarrhythmic therapy in patients with arrhythmogenic right ventricular cardiomyopathy. *Heart Rhythm* 2017;14:564-9.
- 99.** Philips B, Madhavan S, James C, et al. Outcomes of catheter ablation of ventricular tachycardia in arrhythmogenic right ventricular dysplasia/cardiomyopathy. *Circ Arrhythm Electrophysiol* 2012;5:499-505.
- 100.** Riele Te ASJM, Ajjola OA, Shivkumar K, Tandri H. Role of bilateral sympathectomy in the treatment of refractory ventricular arrhythmias in arrhythmogenic right ventricular dysplasia/cardiomyopathy. *Circ Arrhythm Electrophysiol* 2016; 9:e003713.
- 101.** De Ferrari GM, Dusi V, Spazzolini C, et al. Clinical management of catecholaminergic polymorphic ventricular tachycardia: the role of left cardiac sympathetic denervation. *Circulation* 2015; 131:2185-93.

KEY WORDS arrhythmia, cardiac arrest, electrocardiogram, inherited, management, recurrence

APPENDIX For supplemental tables, please see the online version of this paper.



Go to <http://www.acc.org/jacc-journals-cme> to take the CME/MOC/ECME quiz for this article.